

An Update on the Management of Severe Crush Injury to the Forearm and Hand



Francisco del Piñal, MD, Dr. Med.^{a,*}

KEYWORDS

- Crush syndrome • Hand • Compartmental syndrome • Free flap • Hand revascularization
- Microsurgery • Frozen hand

KEY POINTS

- Microsurgery changes the prognosis of crush hand syndrome.
- Radical debridement should be followed by rigid (vascularized) bony restoration.
- Bringing vascularized gliding tissue allows active motion to be restored.
- Finally, the management of the chronic injury is discussed.

INTRODUCTION

Severe crush injuries to the hand and fingers often carry an unavoidably bad prognosis, resulting in stiff, crooked, and painful hands or fingers. In follow-up, osteoporosis is often times seen on radiographs. A shiny appearance of the skin and complaints of vague pain may lead the surgeon to consider a diagnosis of reflex sympathetic dystrophy,¹ to offer some “explanation” of the gloomy prognosis that a crush injury predicates. Primary or secondary amputations are the common end options of treatment.

In the authors’ experience, the prompt and precise application of microsurgical techniques can help alter the often dismal prognosis held by those suffering from severe crush injuries. To avoid the progression of a severely crushed hand to a useless hand, one should understand that the pathophysiology involved in the distal forearm, wrist, and metacarpal area is different from that in the fingers. Therefore, this article discusses the pathology and treatment of injuries involving

the distal forearm, wrist, or metacarpal area and fingers separately.

ACUTE CRUSH TO THE DISTAL FOREARM, WRIST, AND METACARPAL AREA OF THE HAND

Clinical Presentations and Pathophysiology

Two striking features after a severe crush injury are

1. The affected joints tend to stiffen and the affected tendons tend to stick.
2. The undamaged structures distal to the area of injury usually get involved.

The trauma appears to have a “contagious” effect that spreads distally, similar to a fire spreading to the higher floors in a skyscraper. There is no satisfactory explanation as to why normal anatomy seemingly spared during the initial traumatic event should convert to abnormality. To most, the consequence, a frozen hand, is more devastating than the original injury, that is, a focal trauma in the forearm (**Fig. 1**).

This article is an update of a previous version originally published in *Clinics in Plastic Surgery*, Volume 44, Issue 2, April 2017.

The author has nothing to disclose.

^a Private Practice, Madrid, Spain

* Corresponding author. Calle Serrano 58-1B, E-28001-Madrid, Spain.

E-mail addresses: drpinal@drpinal.com; pacopinal@gmail.com

Clin Plastic Surg 47 (2020) 461–489

<https://doi.org/10.1016/j.cps.2020.06.003>

0094-1298/20/© 2020 Elsevier Inc. All rights reserved.

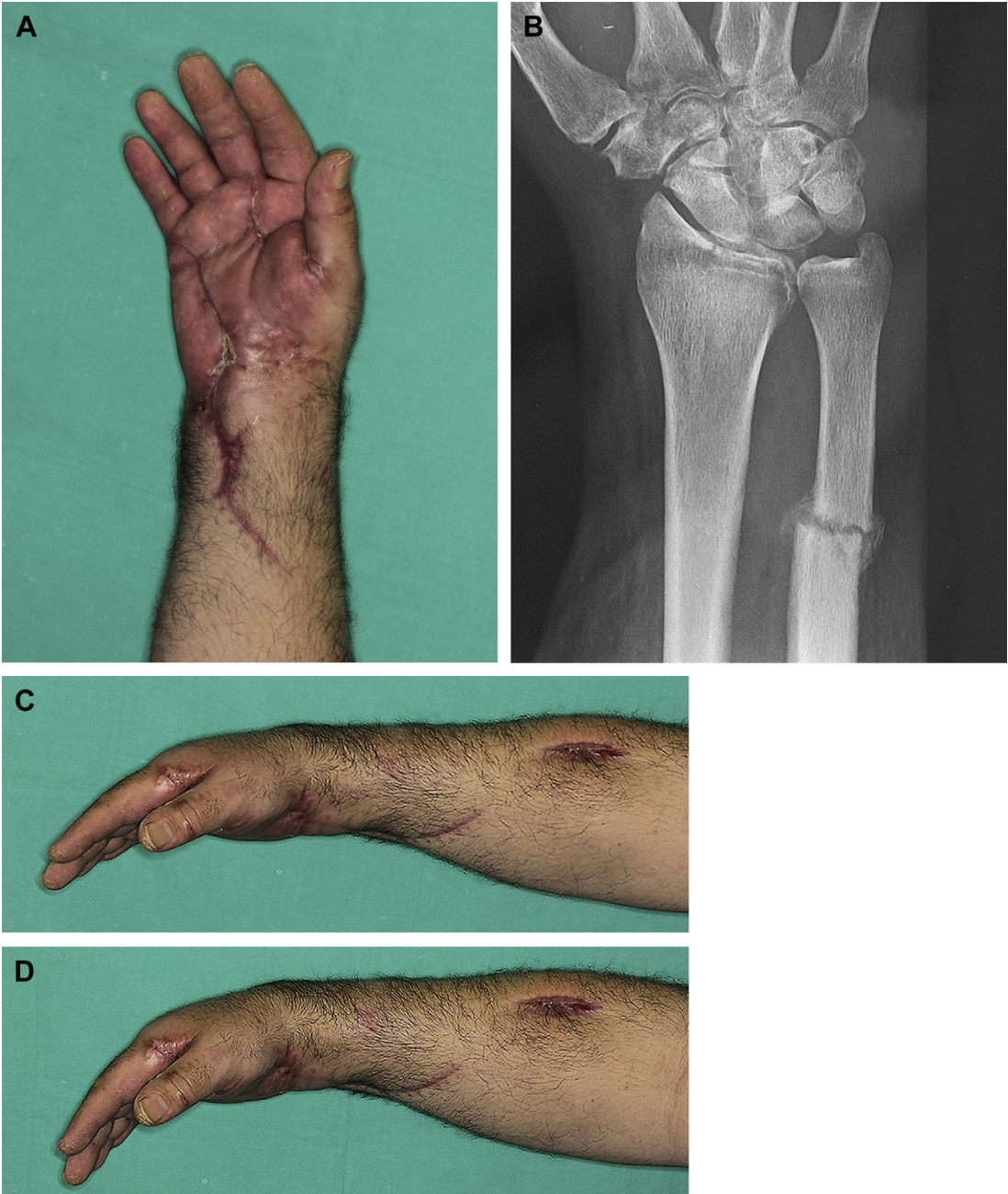

Fig. 1. An example of a frozen hand as discussed. (A) This 44-year-old man was referred 4 months after sustaining a crush injury to his forearm and wrist by a press. Parts of the wounds were left to heal by secondary intention for fear of losing the whole hand. (B) Malunion is present in several areas of the radius, ulna, and carpal bones. It is notable that his fingers became stiff and immobile despite being practically uninvolved. (C) The patient is unable to make a fist. (D) The patient is unable to extend the fingers. (Copyright © 2015, Francisco del Piñal, MD.)

This traumatic event will cause localized devascularization in the forearm and result in healing by fibrosis locally. These facts, however, do not explain the end result of a frozen hand, which often is very painful. The authors attempted to reveal

mysterious pathophysiology of the crush syndrome of the hand, but such attempts have not been fruitful.²

In exploring the pathophysiology, the following questions can be posed: *What causes a healthy*

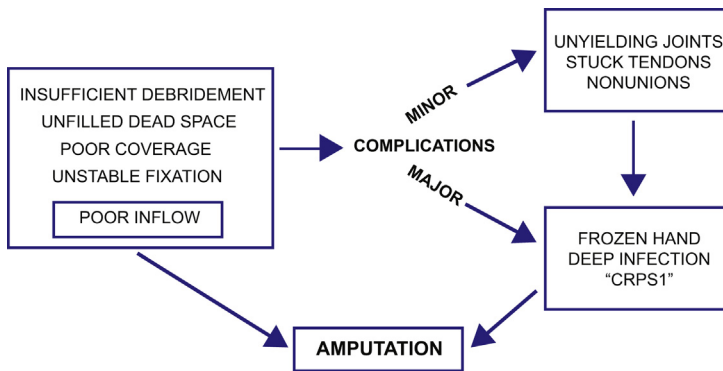


Fig. 2. Flowchart showing the natural progression in mismanagement of complex injuries. CRPS1, complex regional pain syndrome.

tendon to be unable to glide? Or a normal joint to stiffen? Or an uninjured finger to deviate? Several factors can shoulder some of the blame: insufficient debridement, the presence of dead space that fills with debris or hematoma, unstable fixation, and poor coverage. The underlying commonality with these factors is that they contribute to the formation of an enormous amount of fibrotic and scarred tissue. All of them are responsible for a delay in the commencement of active motion, which leads to the loss of tendon gliding and joint stiffness. Muscle contracture, secondary to diagnosed or undiagnosed compartment syndrome, would drag the fingers into dysfunctional positions.

Within this chaotic milieu of diminished blood supply, hematoma, unstable fractures, and poor soft tissue coverage in severe crush injuries, it is easy to foresee that any contaminant could lead to one of the most dreaded complications—deep space infections. Fibrosis and contamination with or without infection result in the dismally functionless “frozen” hand. Furthermore, chronic, unremitting pain is a common component of this syndrome in its later stage. Although a handy acronym “CRPS1” (complex regional pain syndrome) could offer an easy explanation to the onset of pain, a more logical and clearer explanation is that the nerves are either unable to glide and thus causing pain without movement (neurodesis) or ischemic in the confines of heavy scarring. The discomfort is exhausting for the patient both physically and psychologically, and amputation may be needed as the endpoint treatment (Fig. 2).

MANAGEMENT

With the diligent and quick application of the appropriate techniques, a surgeon can halt the progression from crush injury to frozen hand, illustrated in Fig. 2. It is hoped that aggressive

operative management will result in a better functioning hand in the setting of an admittedly devastating injury. Management keys are to address each of the factors that lead to the poor results. Because of the complexity in the decision-making process and the technical expertise required in the treatment, it is crucial that the utmost care be undertaken by a skilled team of surgeons. With minimal variations, management focuses on addressing the 4 pillars in the listed order:

1. Debridement
2. Bone management
3. Neurovascular structures damaged
4. Soft tissue defect

Radical Debridement

In the setting of a severe crush to the forearm and the hand, there is a large amount of devitalized or threatened tissue. The devitalized tissue is a nidus for an inflammatory response, creating a wound bed that heals primarily through the means of fibrosis. This results in a massive amount of scarring. Reducing the burden of dead or dying tissue is paramount to promoting the revascularization of bone as well as for aiding tendon gliding.

When the crush injury involves the metacarpals, one has to consider debriding the interosseous muscles should they be devascularized and/or denervated. Most of the blood supply to the interosseous muscles enters proximally,³ and an injury to the carpal arch unavoidably impairs the arterial inflow into the deep muscles of the hand. In addition, compartment syndrome in the hand may occur with minimal clinical symptoms and remains difficult to diagnose.⁴ Such compartment release should occur with low suspicion to preempt future dysfunction.

When the crush injury occurs at the carpal level, severe derangement of the carpal architecture—

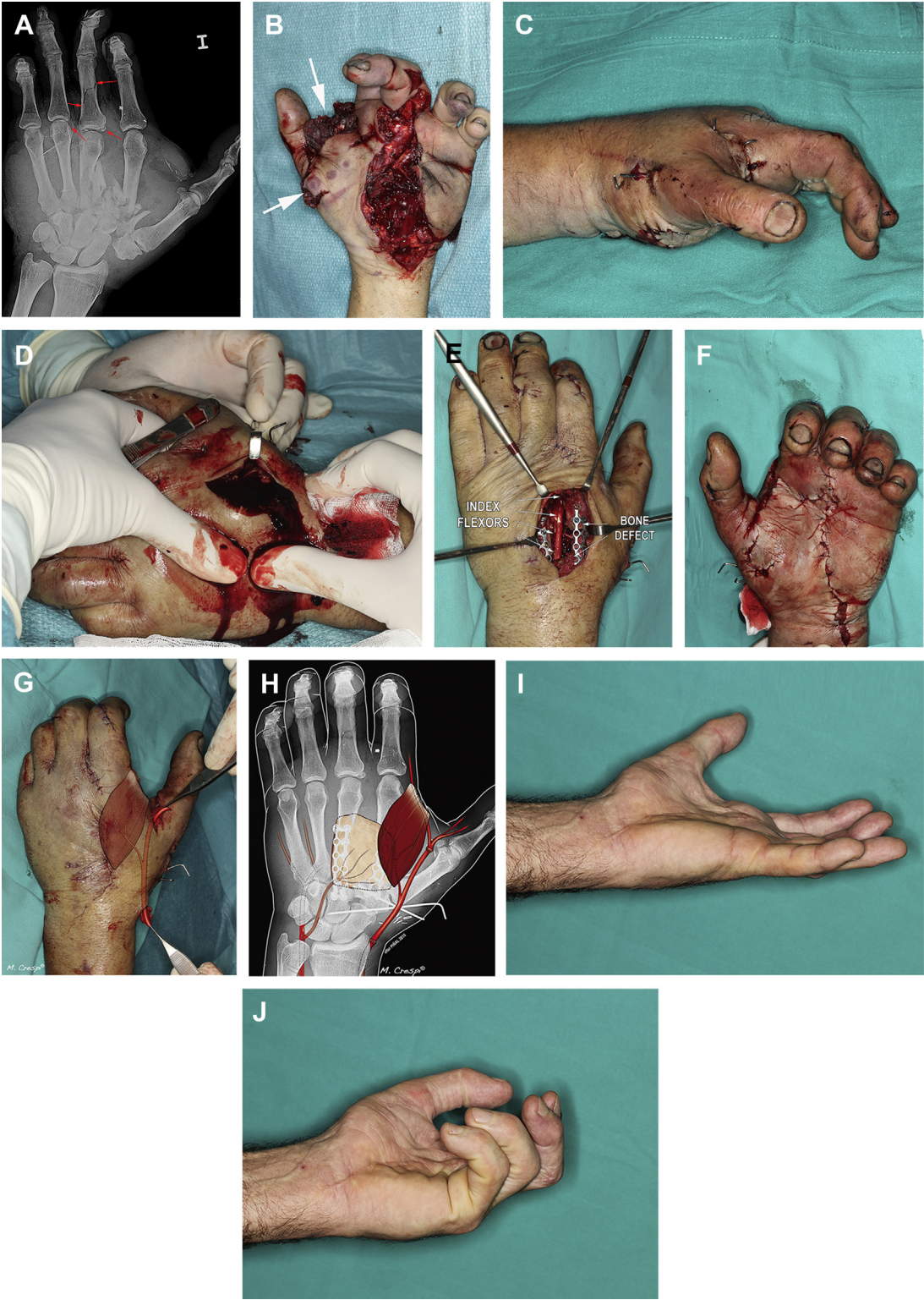

Fig. 3. (A, B) Massive crush injury at the central portion of the hand. Debridement and primary stabilization were carried out as an emergency. Notice that the first web space and thenar musculature (*arrows*) suffered hydraulic extrusion. The radial side of the hand had marginal blood supply, with Doppler signals in the dorsum of the thumb only. (C, D) Three days after the injury, secondary to hematoma and edema, a massively swollen “balloon”

including floating carpal bones, disruption of the deep carpal arches, and potentially hand devascularization—can be expected. Acute hand amputation is not rare,⁵ and late amputation due to deep hand infection is unfortunately common. Amputation is not surprising in this scenario, because the entire central portion of the hand is deprived of its arterial inflow, and potential interosseous muscle necrosis may occur if revascularization is needed.²

Interestingly, simple debridement of this central devitalized tissue can lead to further problems because the dead space created may fill with blood upon release of the tourniquet.⁶ This central hematoma might become secondarily infected, and if not infected, it may still lead to the formation of densely fibrotic tissue, with both carrying an ominous prognosis. The only way the authors found to manage this central dead space is with coverage with a well-vascularized free muscle flap. The muscle flap contours well to the 3-dimensional defect and changes the local environment from scar formation to well-padded, well-vascularized tissue.⁶ A vascularized bone graft may be needed as a solution in selected cases (**Fig. 3**).

Bone Injury or Defect

Typically, a crush injury does not cause simple fractures only, but rather a mixture of simple and comminuted fractures that are often characterized by cortical shattering and free cortical fragments. Primary or secondary bone loss after debridement is frequent. Furthermore, when the injury area includes a joint, the fracture may burst into small, nonfunctional pieces, making joint reconstruction impossible. Despite that specific fractures need different treatments, it is important to note, however, that achieving rigid fixation with minimally invasive techniques permits early commencement of active range of motion with tendon gliding and causes less local devascularization. In the metacarpals and phalanges, the authors usually achieve satisfactory results with the use of intramedullary cannulated screws,⁷ and stable fixation is achieved in minimal time with no dissection and devascularization of the tissue (**Fig. 4**).

If minimally invasive techniques (eg, fixation with intramedullary cannulated screws) are not feasible for fracture fixation, then plate fixation is the next option. Both methods will allow for early motion, diminishing the risk of adhesions. It is not always possible to perform fixation with ideal results. When a joint has severe damage that prevents functional recovery, it is best to replace the joint. This especially applies when the joint injury occurs in the setting of severe soft tissue injury (**Fig. 5**). Although this approach seems very aggressive, the reward is often a much better end result with overall less patient suffering and faster healing times. One should bear in mind that early rehabilitation is of the utmost benefit in *all* hand trauma cases and of even more benefit as the degree of injury increases.

Unlike crush injuries in metacarpal or phalangeal regions, major carpal injuries can rarely be fixed rigidly enough as to allow for early motion as the concomitant ligamentous injuries require prolonged immobilization times. If rigid fixation is unfeasible, then Kirschner wires and other devices are used as needed. Fortunately, at the wrist level, tendons adhesions are very forgiving, much the same as with zone III or IV flexor tendon injuries, and tolerate some delay in starting mobilization. Furthermore, with wrist immobilization, the fingers can still be allowed to move, preventing tendon adhesions at the wrist.

At the level of the distal radius, the preferred method of rigid fixation, especially with joint involvement, is with volar locking plates. When the fracture involves the shaft of the radius, multiple, shattered, devascularized fragments are commonly seen.

Very severe crush injuries often require a wide, and often both dorsal and volar, approach to appropriately manage the bony injury. This, in turn, creates an increased need for flap coverage. Although this may be a potential drawback, liberal usage of free tissue transfer will often benefit patients by virtue of the fact that the surgeon can better radically debride any tissue of dubious vascularity as well as for allowing the addition of subcutaneous tissue for better tendon gliding.

hand can be seen. (E) The metacarpal length was restored using locking-type plates. An estimation of the size of the dead space can be inferred from the fact that the flexors are visible from the dorsal wound. (F) After fixation, the blood supply to the radial side of the hand was still marginal: compare the paleness of the thumb, index, and middle fingers to the pinkness of the small and ring fingers. (G) The extensor digitorum brevis was used to obliterate the dead space and restore pulsatile flow to the thumb, index, and middle fingers by bypassing the zone of injury from the radial artery to the princeps pollicis artery. The massive bone defect was reconstructed with a vascularized medial femoral condyle graft, including a generous component of soft tissue (H) (see also **Fig. 7**). (I, J) The patient declined further surgery that was advised to improve extensor tendon gliding (an adipofascial flap). Despite this, the patient achieved a reasonable functional status.

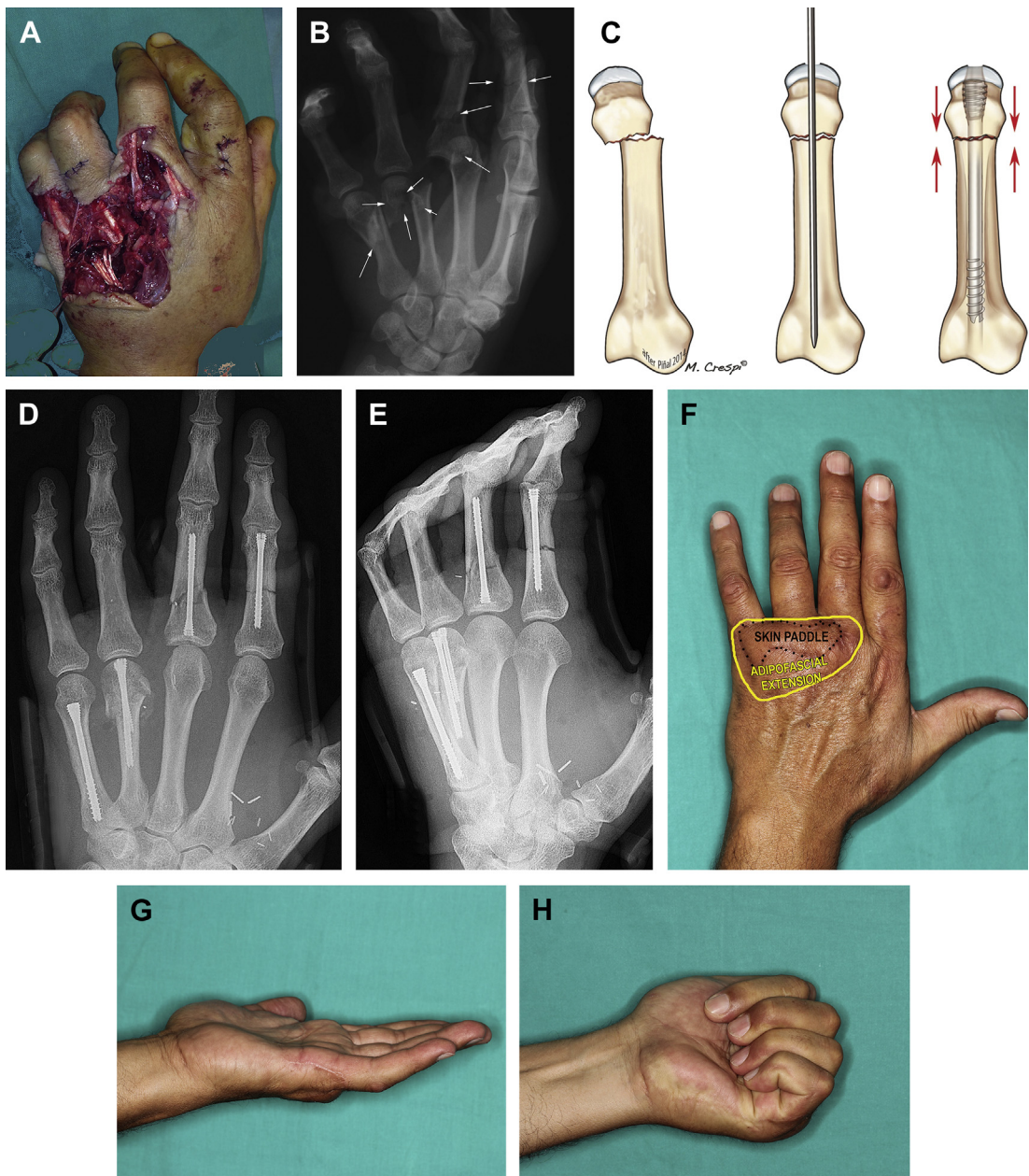
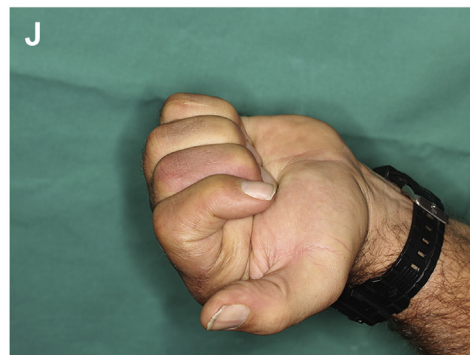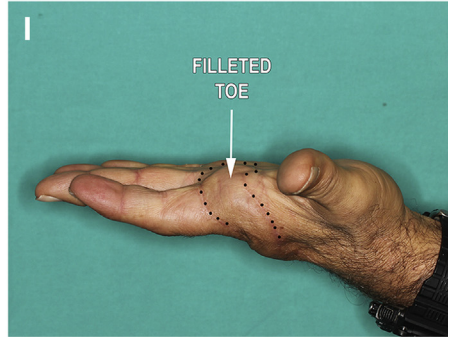
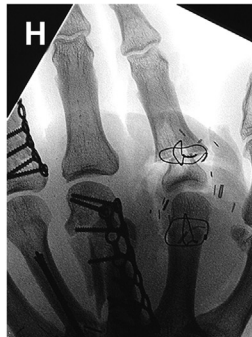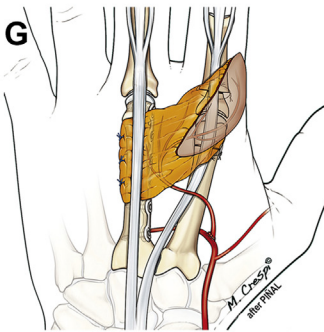
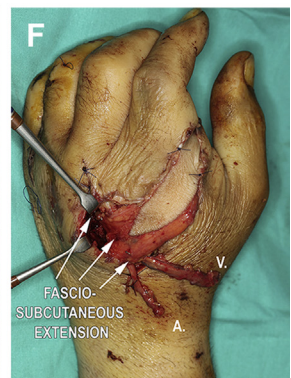
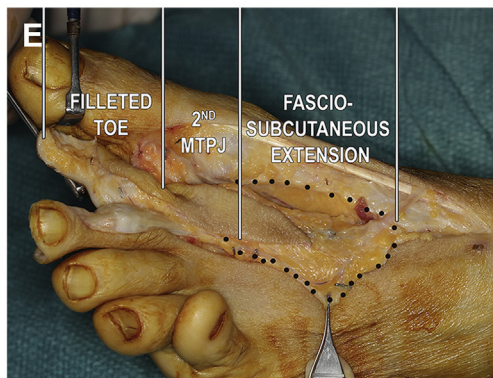


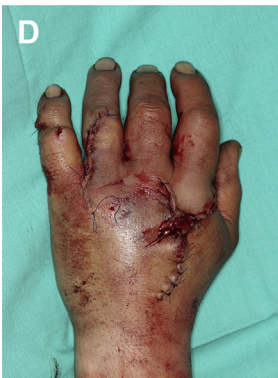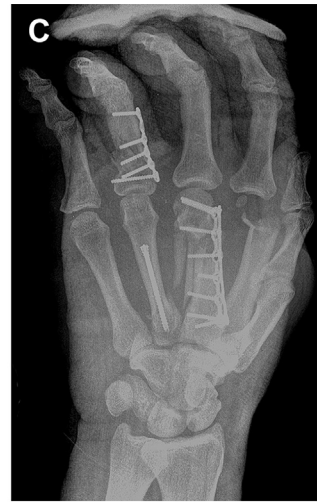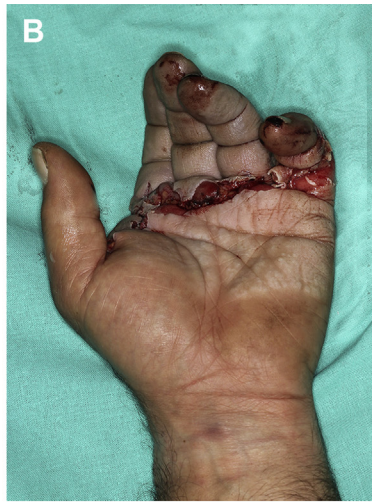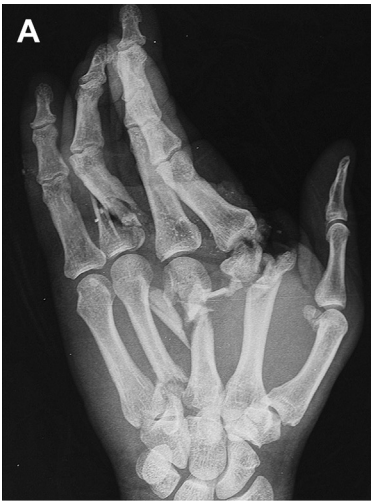Fig. 4. Multiple fractures managed with intramedullary cannulated screw fixation in a patient who sustained a crush injury. (A, B) Soft tissue defect and extensor tendon laceration of the ring and little fingers and open fractures (arrows) with severe comminution of the head of the ring finger metacarpal. (C) Sketch summarizing intramedullary fixation with cannulated screws placed into the metacarpals. (D, E) The fractures were treated with a standard 3.0-mm headless cannulated screw for the index finger; a 3.0-mm antegrade screw for the comminuted middle finger; a Y strutting for the ring finger (and primary bone grafting of the defect); and a 4.0-mm-diameter screw for the small finger. (F) An adipofascial free flap was used for coverage to provide a gliding environment for the extensor tendons in this severe injury. One year later, minimal flap tailoring and partial hardware removal were performed. (G, H) Clinical result at 2 years. (Copyright © 2015, Francisco del Piñal, MD.)

In any locations, cortical bone fragments devoid of periosteal connections are best debrided away and replaced with cancellous bone. This approach will speed up wound healing times without an

increase in infection rates. When the defect is large, or when there is a large area of tissue devascularization, cancellous bone grafting alone will not ensure bony union or the bony healing is



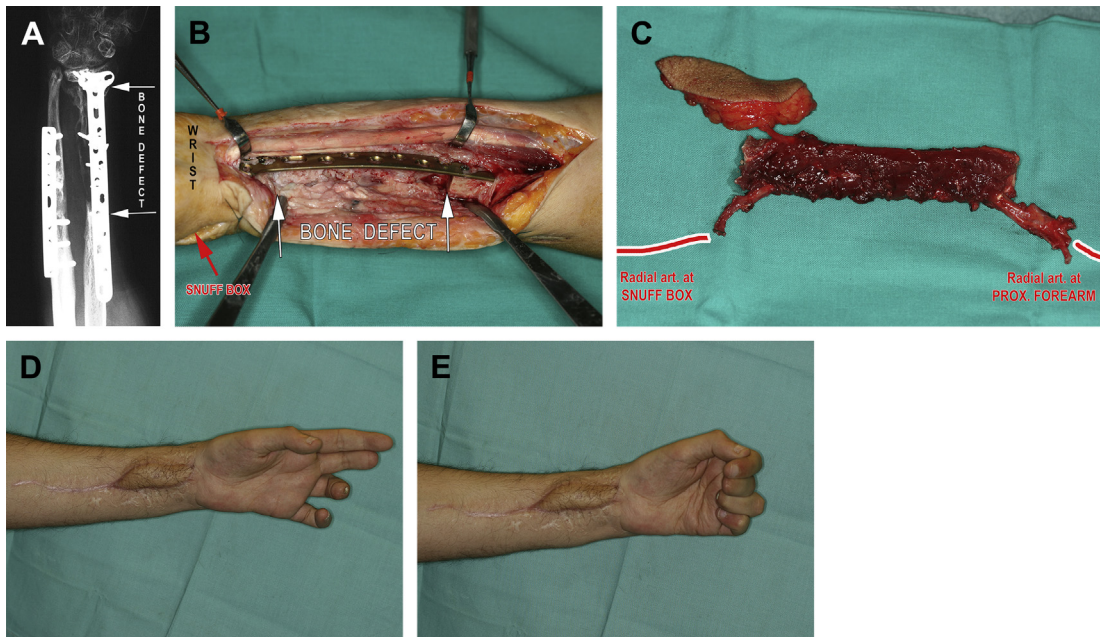


Fig. 6. This patient was seen 18 months after a crush injury to his hand and forearm. Two previous attempts to reconstruct the radius with nonvascularized bone had failed. The patient was wearing a splint to support his painful wrist and nearly frozen hand. (A) In the preoperative radiograms, a faint shadow of the bone graft could be seen. (B) At surgery, the bone graft, which had been replaced by scar tissue, was resected. The plate, despite being bent, was kept in place, as it was providing sufficient stability and maintained the correct length of the radius. The proximal screws in the radius were removed, the wrist distracted, and the fibula slotted into place. Noteworthy here is the lack of fat in the wrist, and the flexors crumpled together. Also, the radial artery had been damaged in the previous surgery and is now indistinguishable from the fibrotic mass. (C) The combined 14-cm radius and radial artery defect were reconstructed by a flow-through fibula flap. A skin paddle was also included to add fat distally and to monitor the reconstruction. (D, E) The generalized stiffness in the hand and wrist was already so established that only limited functional improvement, albeit painless, was achieved despite secondary tenolysis and joint release. (Copyright © 2015, Francisco del Piñal, MD.)

delayed. The cancellous bone grafting greatly interferes with the functional outcome in the authors' experience (Fig. 6).

For this reason, the authors advocate early use of vascularized bone transfer, which is preferable in this situation. Not only will vascularized bone promote rapid healing but also it will resist infection. When the defect is less than 3 or 4 cm, the authors' preferred flap is the medial femoral condyle

flap (Fig. 7),⁹ but the skin island may have variations that may make it less preferential.¹⁰ A vascularized lateral scapular free flap can address both bone and soft tissue defects, but the skin on the back, like the iliac crest, is often too thick. The fibula has an innate problem of no guaranteed blood supply when used as small segments. In the senior author's observation, the fibula flap only has a secondary role in treating small complex defects.

Fig. 5. (A, B) This 45-year-old heavy smoker had his central 3 fingers devascularized in a crush injury, sustaining multiple comminuted fractures. (C, D) Fixation and revascularization were carried out in the emergent setting. The index finger metacarpophalangeal (MP) joint was beyond repair and debrided. The wounds were temporarily closed by allowing joint collapse. (E, F) Five days later, the soft tissue defect was re-created. A composite metatarsophalangeal joint from the second toe, including a filleted toe and a dorsal fasciosubcutaneous extension⁸ flap, harvested to provide tissue to aid in gliding dorsally, was transplanted. The third metacarpal also underwent bone graft in this second stage. (G) Sketch showing the inseting of the flap to separate the hardware from the extensor tendon. (H) Intraoperative fluoroscopy. (I, J) Result at 6 months. No other surgery was performed nor is planned. The lack of full extension of the PIP joint is probably due to the lack of intrinsic muscles of the index finger (ie, a traumatic claw deformity) and could be corrected by a lasso-type operation. The patient is very pleased with his results and declines further reconstruction. (Copyright © 2015, Francisco del Piñal, MD.)

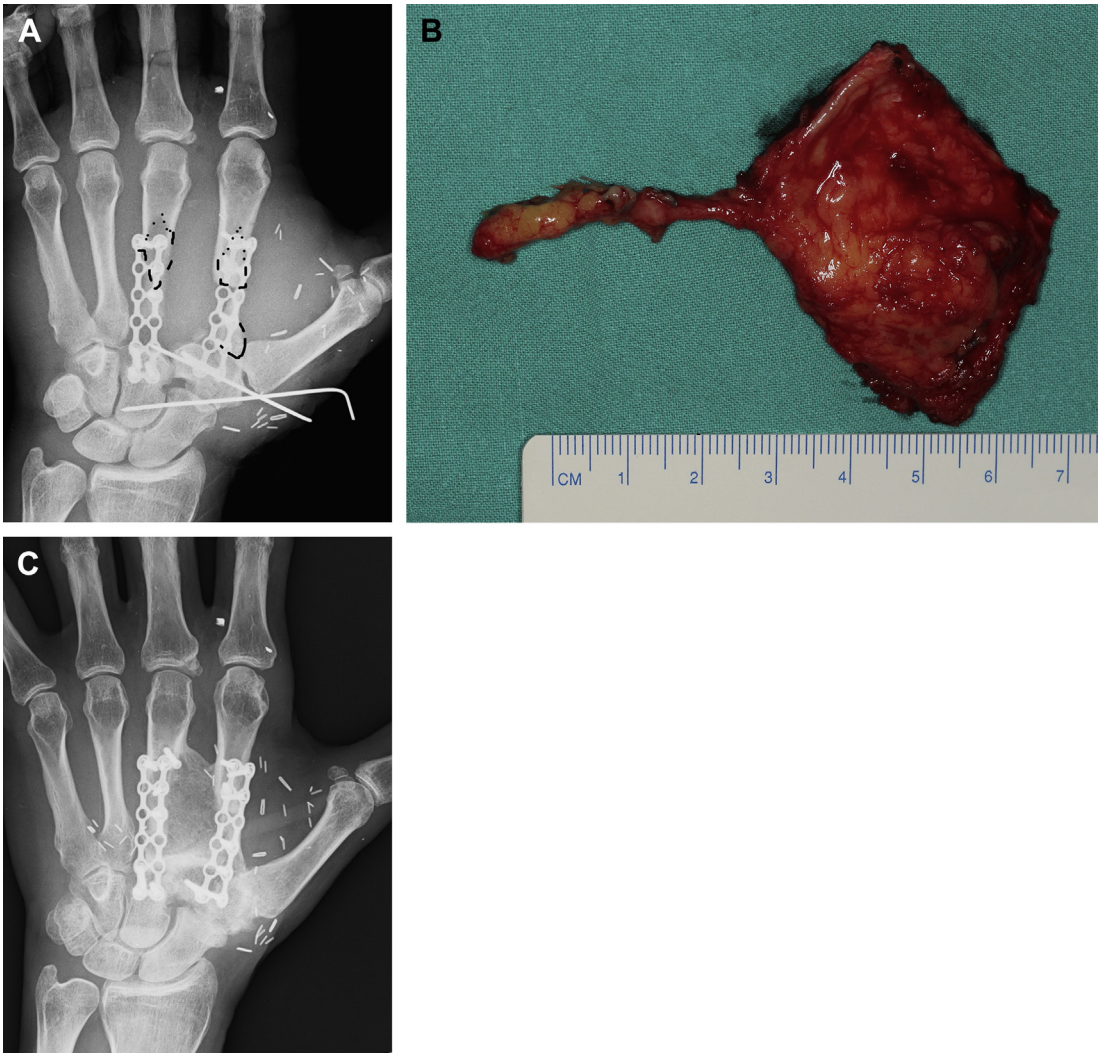


Fig. 7. (A) A large defect of two-thirds of the anterior aspect of the second and third metacarpals. The bony lengths were maintained temporarily with locking plates. (B) A 4×3 cm medial femoral condyle corticoperiosteal flap stabilized in place with 2.0-mm screws allowed the authors to span the defect and permitted immediate range of motion. (C) A plain radiograph 7 months after the operation (the same patient as in Fig. 3). (Copyright © 2015, Francisco del Piñal, MD.)

Neurovascular

Combined injuries are often associated with major arterial injuries that if unrecognized or mismanaged may lead to primary or subacute amputation.^{5,11} Typically, the radial, ulnar, and/or both carpal arches are avulsed. In this setting, emergency reconstruction is a must. The senior author is a firm advocate for the use of arterial grafts instead of reverse vein grafts at the time of reconstructing the superficial carpal arch. It is technically much easier to suture an artery to an artery and vessel caliber discrepancy is avoided. Furthermore, the surgeon can combine the arterial

graft with a soft tissue flap to help to close the dead space. As for graft patency rates, the cardiac-surgery literature, which is much more extensive, illustrates the excellent long-term patency rates of arterial grafts. Overall, the speed of surgical repair is essential in these complicated settings.

There are several sites from which to harvest donor arteries, including the deep inferior epigastric, thoracodorsal, contralateral radial artery, and descending femoral artery, with each having its advantages.¹² As most of the authors' surgeries are carried out under regional anesthesia, the senior author prefers an artery from the dorsum of

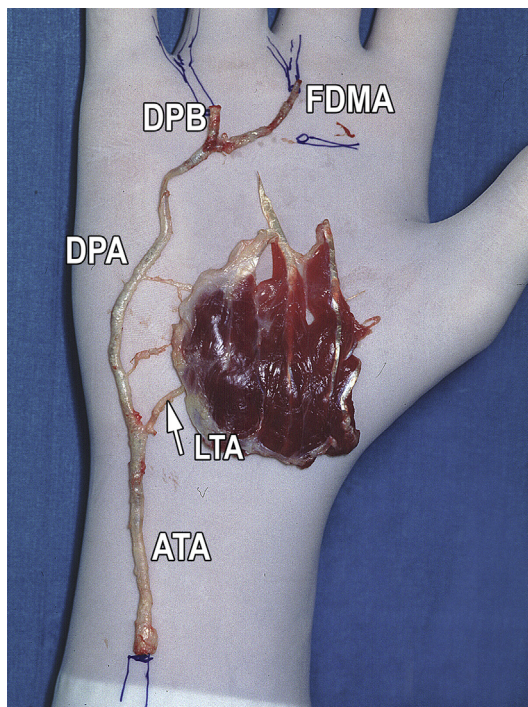


Fig. 8. In this cadaveric simulation, the deep plantar branch and the first dorsal metatarsal arteries are to be connected to the common digital arteries. ATA, anterior tibial artery; DPA, dorsalis pedis artery; DPB, deep plantar branch; FDMA, first dorsal metatarsal artery; LTA, lateral tarsal artery. (Copyright © 2015, Francisco del Piñal, MD.)

the foot¹³ (when a toe transfer is not foreseen) or the deep inferior epigastric artery in the case that a toe transfer may be needed in the future (**Fig. 8**).

As opposed to the relatively high incidence of major arterial injuries, the incidence of tendons and nerve injuries is relatively low with crush mechanisms. If there is nerve damage, for the most part, the nerves are avulsed, and in these cases, the authors defer the reconstruction for some days to weeks. Tendons are repaired primarily if possible. Occasionally, the surgeon can place a silicone rod in the path of a future tendon transfer. This allows the surgeon, in a second stage, to pass a tendon graft using the rod as a guide and without risking damage to previously repaired structures. This same maneuver can be used to span nerve defects. Regarding the nerves, as mentioned before, primary defects are rare. A much more common problem, discussed later, involves a healthy nerve that secondarily becomes entrapped in scar and thus provokes “causalgic” pain.

Defect Coverage

As a general principle, the authors avoid local flaps for defect coverage in crush injuries to minimize local tissue insult. To minimize local damage, they are staunch advocates of using the “*reconstructive elevator*” as opposed to the “*reconstructive ladder*.” When a local flap is going to compromise the final result (either in function or in the speed of recovery), the authors opt for reconstruction with a free flap. Although the alternatives are numerous, in the senior author’s practice, moderate defects are treated with gracilis, iliac, or lateral arm flaps. These flaps have the advantage of being near the site of injury or of causing minimal donor site morbidity. The authors have not had any problems with the use of gracilis muscle flaps for coverage in the dorsum of the hand, because this flap is both aesthetically pleasing and it offers the tendon better excursions (**Fig. 9**). The authors do, however, try to avoid coverage with free muscle flaps if they foresee the need for secondary surgery underneath the flap. For large defects, they prefer the anterolateral thigh (ALT) fascial flap or an expanded gracilis (achieved by removing the outer epimysium) flap. In the experience of the senior author, the ALT flap is too thick for use in the hand, and the donor site morbidity is too significant to justify.

Another, less evident, situation where the authors have found the use of free flaps beneficial is after a severe crush trauma at the level of the carpus. Although there may appear to be good soft tissue coverage, the wound bed may be exhausted and without the ability to provide for adequate gliding of the tendons. Fat would undergo necrosis, which leads to the loss of tendon gliding. In this setting, the nerves would also have difficulty gliding, resulting in neurodesis as a source of pain. It is under these circumstances that the addition of a free adipofascial flap may have an astonishing benefit to the patient even in the patients with intact skin coverage.¹⁴

By the same token, “*marginally surviving tissue*” in major trauma will not provide the ideal environment for tissue healing. Complications, such as delayed tendon healing, adhesions, tendon rupture, delayed bone union, and nonunion, will increase dramatically. Even worse, major complications, such as deep infection or amputations, increase exponentially in the setting of marginally surviving tissue. So despite the risk of salvage, the authors strongly recommend that one pursue an aggressive stance in order to head off the spiral of complications that may ultimately lead to hand amputation (**Fig. 10**).

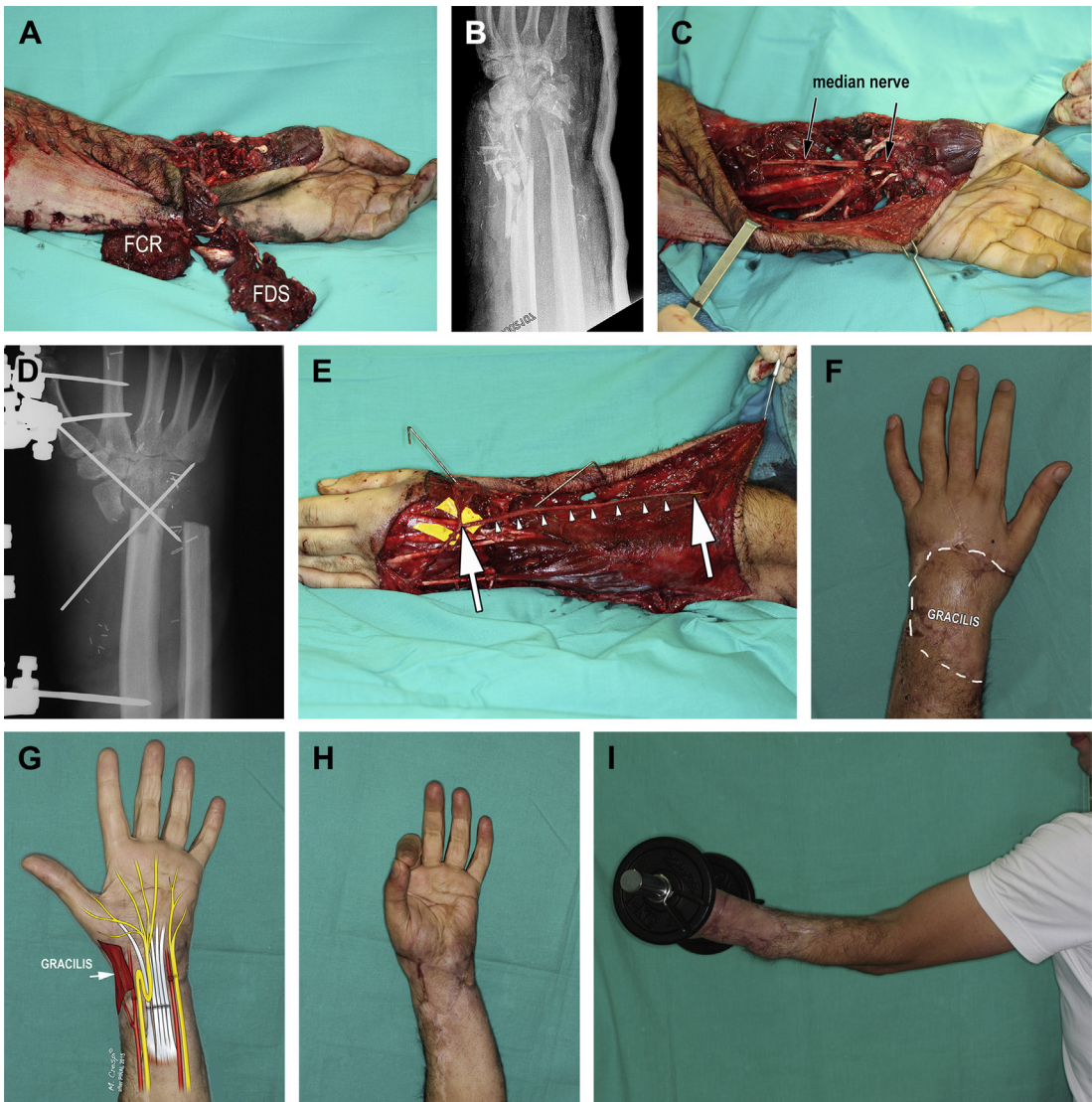


Fig. 9. (A, B) This patient had his forearm crushed by a machine press. Loss of flexor muscles and destruction of the wrist joint are evident. (C) The presence of a normal hand and the median nerve partially in continuity tipped the balance toward reconstruction. Resuscitation of hypovolemic shock was simultaneously performed by the anesthesiologist. (D) To allow for healthy bone healing, about 8 cm of shortening was required. This also allowed primary ulnar nerve and arterial repair. The median nerve was folded on itself. The flexor and extensor tendons were also repaired. (E) Despite shortening of the forearm, a 20-cm saphenous vein graft was necessary to connect the veins of the hand with a healthy vein in the elbow (arrows). (F) The dorsum of the hand, wrist, and distal forearm was covered with a skin-grafted gracilis muscle flap. (G–I) Limited but useful function justified the exhausting reconstructive effort. (Copyright © 2015, Francisco del Piñal, MD.)

TIMING

Ideally, the reconstruction should be done in one stage; however, the complexity of the injury might make it unwise to pursue all the steps in one sitting (**Table 1**). In the senior author's experience, very lengthy surgery increases the chance of making

mistakes, even at the hands of expert surgeons. If at all possible, the night should be for resting. Despite the authors' indoctrination of the importance of immediate free flap coverage, they see no problems in delaying flap coverage for 24 to 48 hours and thereby having a refreshed surgical

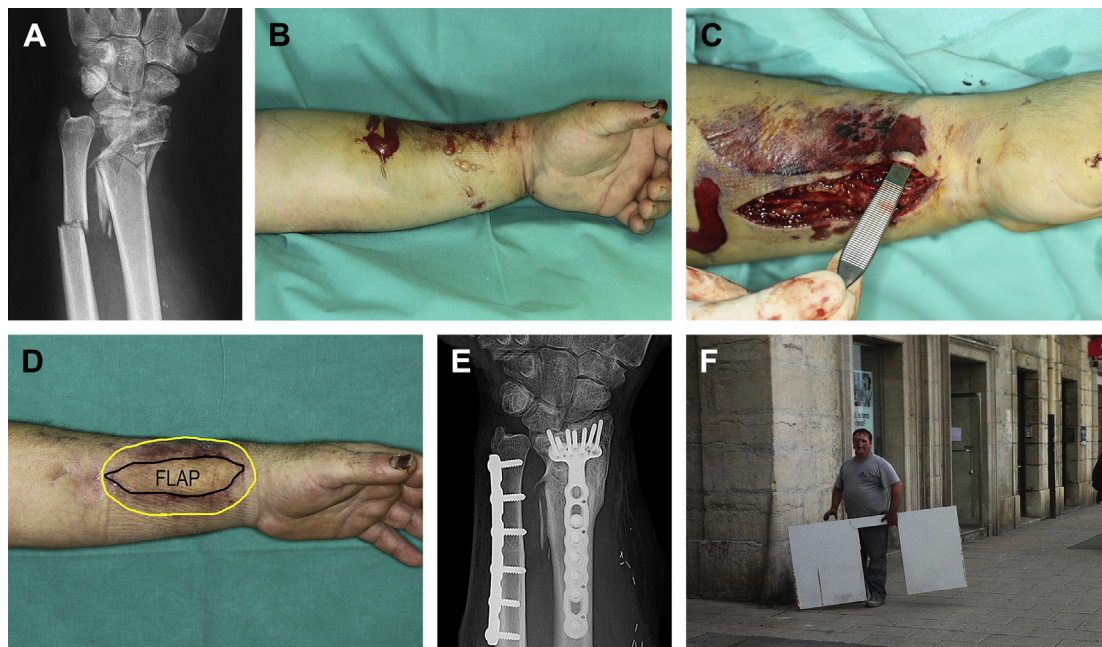


Fig. 10. (A) This patient's forearm was crushed by a brick wall, causing comminuted fractures of the radius and a shaft of the ulna. (B) Skin and wrist swelling is evident at 12 hours. (C) Release of the distal forearm compartments and hematoma evacuation were sufficient for decompression. Although local tissue was enough to cover the plates, it was insufficient to provide a healthy environment for fracture healing and tendon gliding. Note that the skin flap is paper thin. (D) A lateral arm fasciosubcutaneous flap was used to wrap around the bone and provide a healthy fat layer for tendon gliding. Immediate range of motion was started. The patient regained nearly normal wrist motion and 115% grip strength on his affected (dominant) hand. (E) A plain radiograph taken at 1 year. (F) The patient returned to his original occupation. He was photographed here by the senior author, who happened upon him while he was working (with patient permission). (Copyright © 2015, Francisco del Piñal, MD.)

Table 1 Roadmap of management of the severe crushed hand			
	Emergency (and Order of Care)	Second Stage(s) (3–14 d)	Later Stages (mo)
General	1. Radical debridement		
Muscle	2a. Debride doubtful muscle 2b. Release compartments (2c. Placement of rods)	Rods to prepare the path for tendon transfers	(If muscle loss) Tendon transfers Free muscle transfer
Bone	3. Definitive fixation if feasible/restore length if not	<ul style="list-style-type: none">• Definitive fixation if not done• Vascularized bone graft (VBG)• Joint transfers	Tackle delayed union with VBG
Tendon	4. Primary repair when possible	Grafts	Tenolysis/gliding flaps
Blood	5. Revascularize	Additional inflow if needed	
Nerves (rarely severed)	6. Primary repair when possible	Nerve grafts	
Cover	7. (If needed) Free flap (0–48 h)	Replace doubtful cover	
Amputations	(3). Replantation/ectopic replant	Toe transfers	

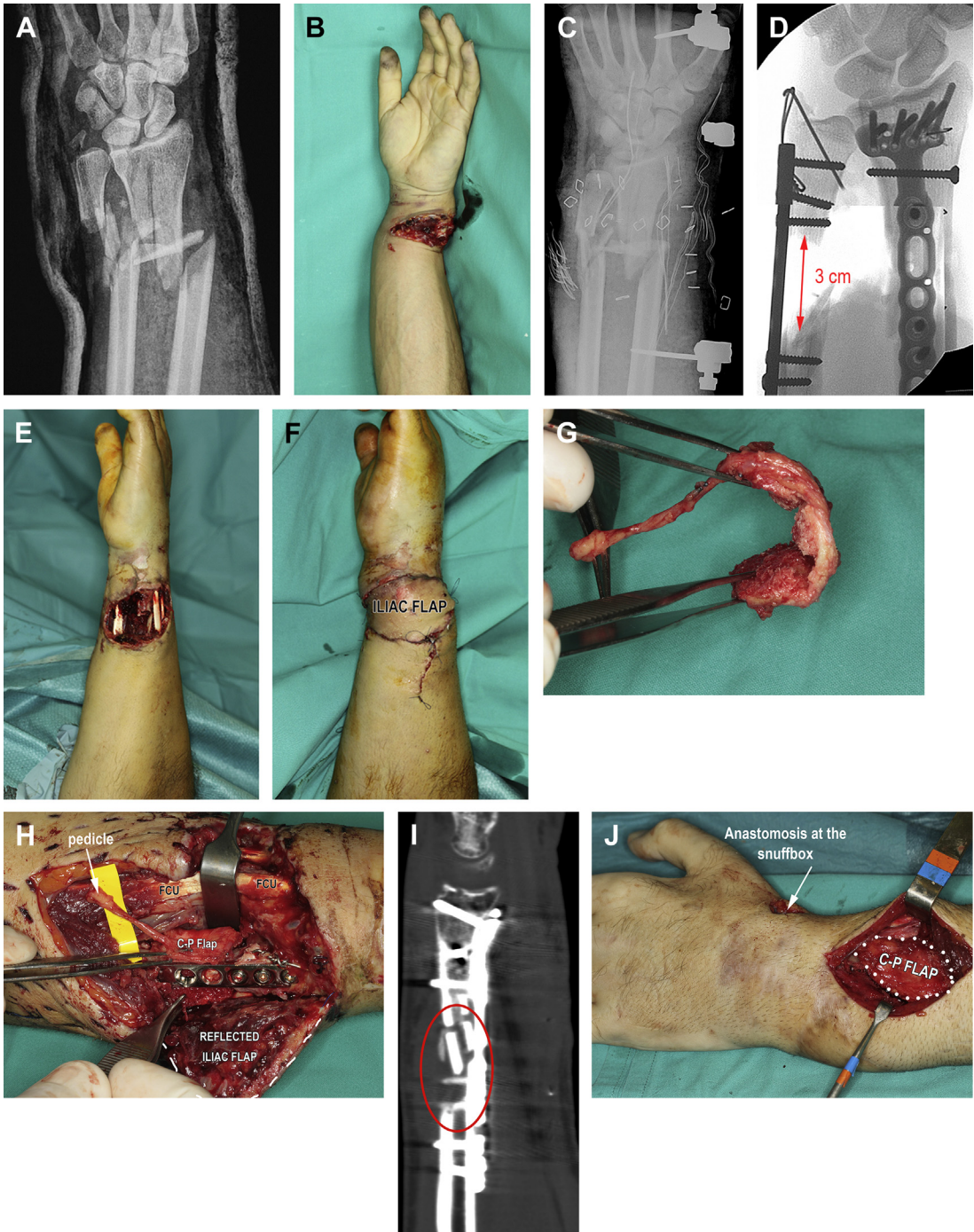


Fig. 11. Multistage reconstruction. (A, B) Hand devascularization and corresponding initial radiographs. (C) Emergency double bypass at the wrist with vein grafts and repair of the tendons were performed. An external fixator temporarily maintained the reduction. (D–F) Three days later, the radius was arthroscopically reduced and fixed with the application of a plate, but the ulna was left with a gap of 3 cm. The ulnar soft tissue defect was covered with an iliac free flap. (G, H) On day 13, the iliac flap was elevated and reflected ulnarly. Notice the vascular repair was protected by the flexor carpi ulnaris. A medial femoral condyle corticoperiosteal flap (C-P flap) was tailored to wrap around the defect opposite the plate. (I) At 6 months, the patient reported a new pain in his radius. A computed tomographic scan revealed an evolving nonunion despite primary cancellous bone grafting. (J) The contralateral medial femoral condyle was used as a graft to treat a nonunion of the radius, and the 2.7-mm ulnar plate was removed concomitantly. (K, L) Result 9.5 months after the surgery. An artistic rendering of the surgery on this patient. (M) The patient felt so well that, without permission, he started going to the gym 2 months later. He is shown here doing pushups in the office 9.5 months after the original trauma. He regained full range of motion. (Copyright © 2015, Francisco del Piñal, MD.)

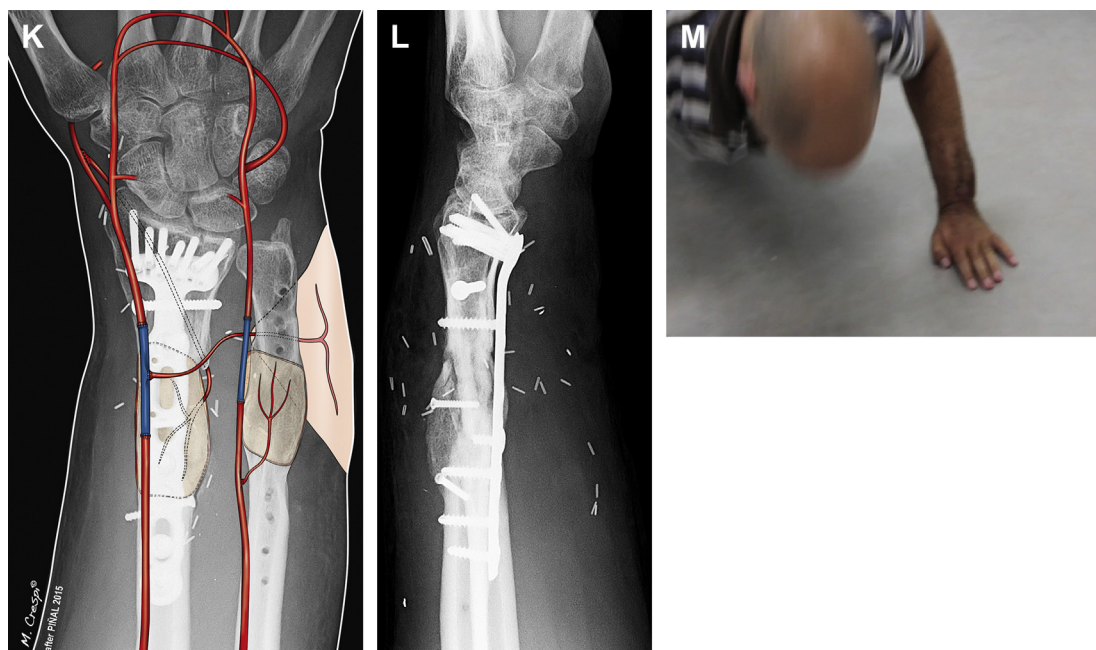


Fig. 11. (continued)

team. The authors also see no problems in performing the initial debridement and vascular reconstruction with temporary bone fixation at the time of presentation and delaying definitive closure and fracture management. In the authors' opinion, with the use of a logical roadmap, staging the reconstruction will not alter the final results (Fig. 11).

COMPLICATIONS

In the setting of major injuries, such as severe crush injuries to the forearm and the hand, complications are to be expected. They should be handled as aggressively as the original injury; otherwise, the whole reconstruction may be marred. This applies even to seemingly "minor" problems because they can, and often will, result in a major setback. Among the more innocuous complications are delayed wound healing and nonhealing of one of the fractures. In the authors' hands, such cases are *nearly always* managed with the placement of a vascularized bone graft (medial femoral condyle) (see Fig. 11). Some might consider this policy too radical, but a nonvascularized bone graft has no chance in the setting of devascularized tissue, which is the main feature of this syndrome.

A lack of tendon excursion is also commonly seen. Some of the patients may actually have near full passive range of motion but very little

active motion. This is frequently due to the loss of fat (the gliding tissue) that occurs for several reasons, including the original trauma, surgery, or as a result of infection. Fat is extremely sensitive to traumatic damage, and the lack of fat precludes tendon sliding (see Fig. 3). As a preventive measure, the authors always try to include some vascularized fat surrounding their flaps when they harvest them to tackle this problem. As stated previously, the lack of fat can also contribute to pain and lack of cooperation at the time of rehabilitation.

The appearance in the immediate postoperative period of any skin flap struggling should raise *red flags*. This is going to be a source of major problems in many of the cases and should be monitored by the leading surgeon. Even if the flap ultimately survives, the "minimal" consequence will be that the fat underneath the ischemic flap will die, worsening the gliding environment for the tendons in the area. However, this complication is minor compared with the most common, which is a deep wound infection. In the senior author's experience, most cases of deep infection have been the consequence of "minor" tissue flap ischemia, which, in time, leaves devascularized bone exposed and sets the stage for a deep infection. One has to understand that small amount of nonfractured bone may be of no consequence in any other scenario, but in the setting of a crush injury, that "bit of bone" is devascularized

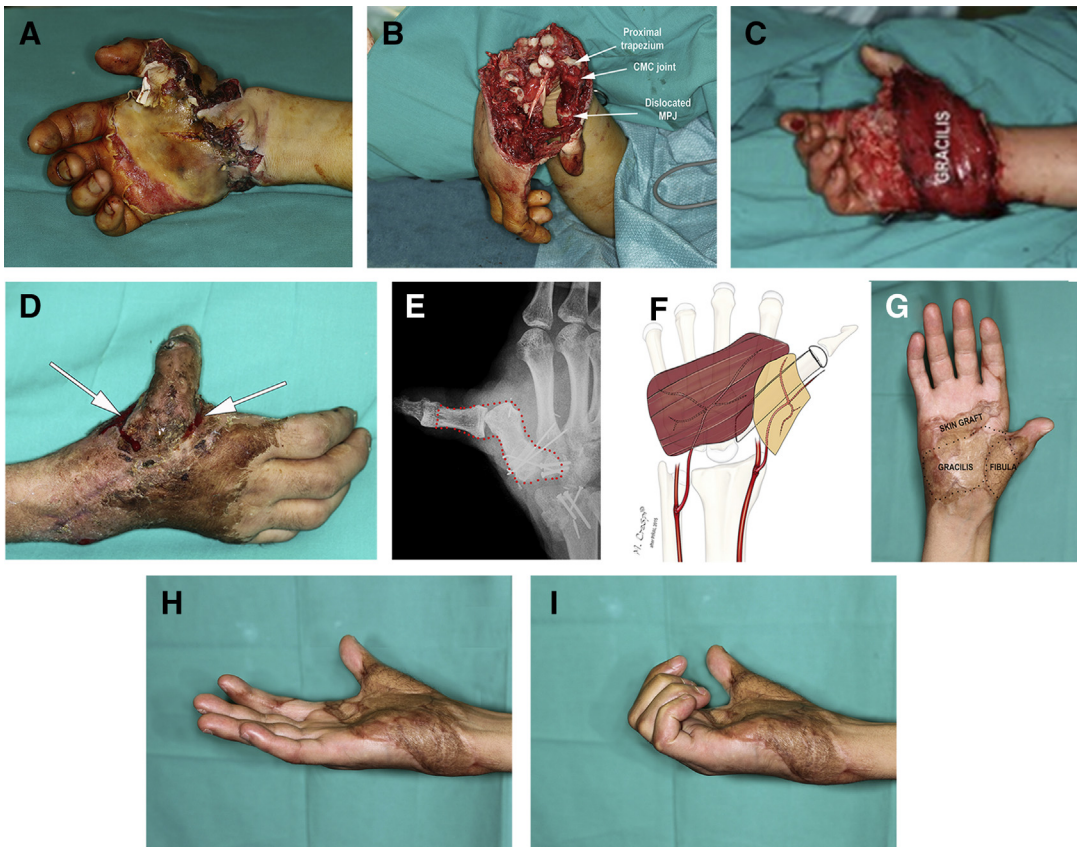


Fig. 12. (A) This crushed hand was referred 6 days after initiating care elsewhere for impending amputation after a hot press injury. The palm suffered a third-degree burn. (B) Emergency debridement gives a better view of the severity of the initial injury. Notice that the thumb is actually hanging by a minimal skin bridge. The MP joint is dislocated. All could be repositioned but were marginally vascularized. (C) After debridement, which included the entire proximal carpal row, the thumb was revascularized and a free gracilis was used for coverage. The confluence of the gracilis and the healthy native tissue over the first metacarpal showed signs of delayed healing (arrows), which was expected to heal by secondary intention and thus was managed conservatively. (D) Over the ensuing weeks, a "minor" infection that began on the "minimally" exposed first metacarpal resulted in a major deep infection with multiple draining sinuses around the thumb (arrows) and destruction of the thumb metacarpal, the MP joint (whose reconstruction had failed), the proximal phalanx, the carpometacarpal joint, the trapezium, and half of the trapezoid. All of the prior reconstruction had to be excised (marked in red dots in E). Fortunately, the wrist could be spared during the debridement, and some motion was preserved. (F) A fibular osteocutaneous flap spanned the defect of the thumb and helped clear the infection while also resulting in an immobile thumb. The deleterious effects of delaying range of motion in the rest of the hand can also be appreciated in these pictures (G–I). (Copyright © 2015, Francisco del Piñal, MD.)

and has minimal resistance to infection. The infection then spreads and results in major catastrophe unless aggressive measures to replace the flap are taken (**Fig. 12**). Seemingly overly aggressive attitudes may salvage the patient from a poor outcome (**Fig. 13**).

MANAGEMENT OF ACUTE CRUSH TO THE FINGERS

Crushed finger injuries, although often less severe, may portend considerable disability and

morbidity, and thereby, become a greater surgical challenge. The "minor" variants in this subgroup consist of finger injuries where the skin envelope is preserved yet the arterial supply has been interrupted (**Fig. 14**). This can be due to either direct injury to the vessel by a bone spike or an arterial avulsion as a result of the vessels being tethered by the local fascia or side branches. Major clues that would lead one to suspect vascular impairment are phalangeal fractures with longitudinal fractures lines, fractures with significant displacement, color changes, tingling, and numbness.

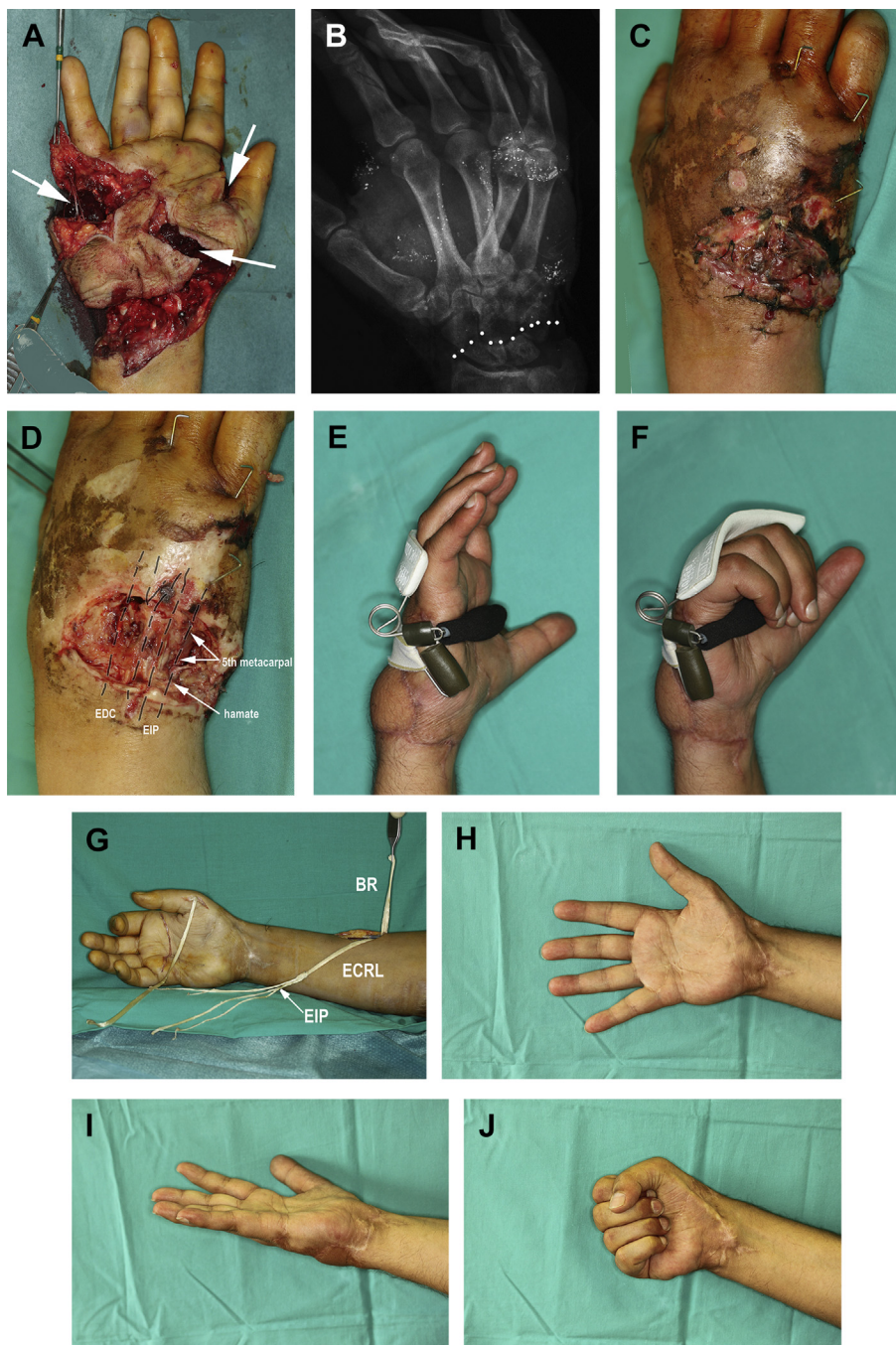


Fig. 13. (A) This 35-year-old man sustained a crush to his hand and wrist. In addition to the extrusion of the intrinsic musculature (*arrows*), all flexors and most of the extensor tendons were also severed. The radial and ulnar artery and median and ulnar nerves were also divided. All structures were repaired primarily, and blood flow was restored to the hand. (B) The patient also had perilunate (*dots*) and carpometacarpal (3–5) dislocations, which attest to the severity of the injury. Only Kirschner wires were used for fixation. (C) At 10 days after surgery, there was viable granulation tissue intermingled with marginally viable skin flaps and unstable skin grafts, threatening to expose the distal carpal row and metacarpal bases. (D) Very reluctantly, the senior author decided to explore this recently revascularized hand. The wounds were debrided, leaving the bone and repaired tendons exposed, and a free lateral arm flap was inset to provide healthy tissue. (E–G) An anticlaw splint was worn, and at 7 months, the function of intrinsic muscles were replaced with tendon transfers in the usual fashion for ulnar-median nerve palsy (extensor carpi radialis longus tendon grafts to intrinsic muscles, brachioradialis tendon to the lateral sesamoid, and extensor indicis proprius tendon to the abductor pollicis brevis). (H–J) Function at the 18-month follow-up visit. This patient illustrates the importance of being aggressive to prevent deep infection and the need to plan out the stages to be used in the reconstruction. (Copyright © 2015, Francisco del Piñal, MD.)

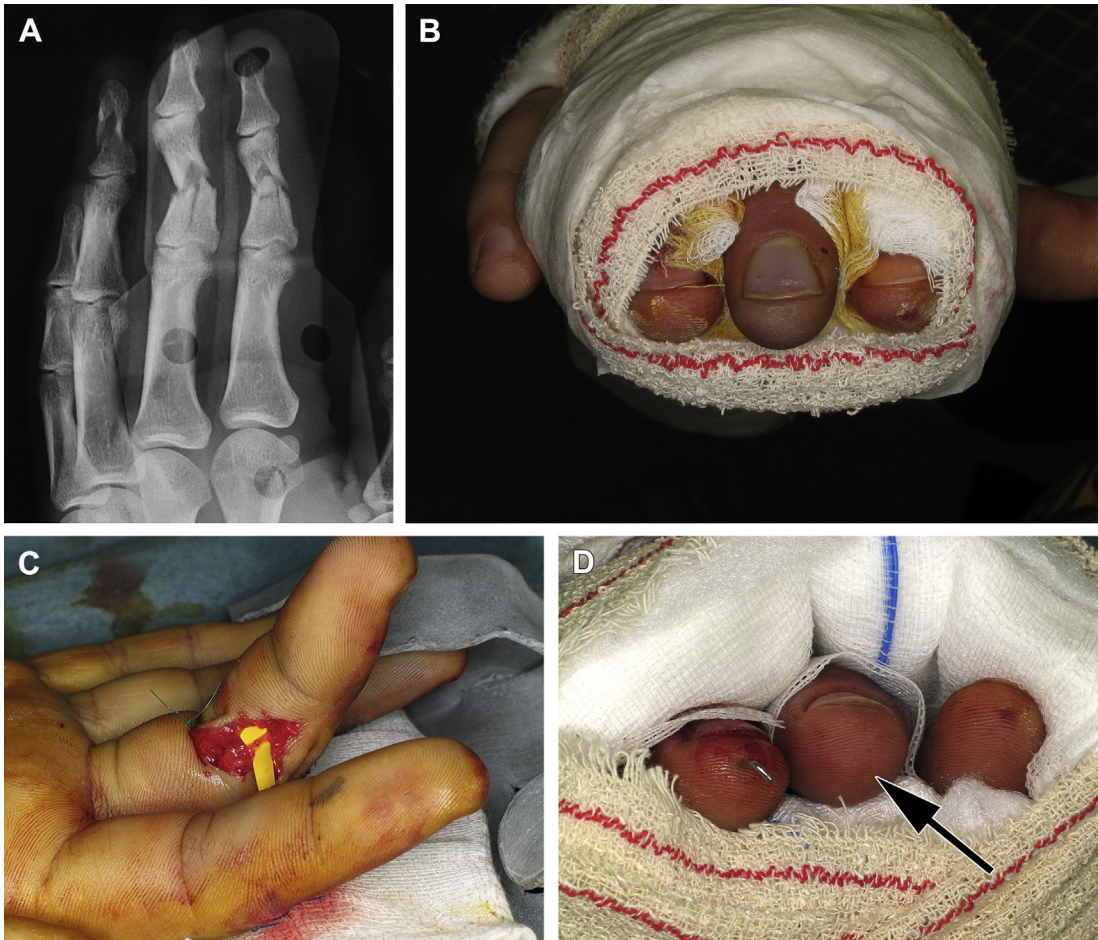


Fig. 14. This patient sustained a crush injury to his fingers 28 hours before consultation. Bluish discoloration, tingling, and numbness prompted him to seek a second opinion. (A) The radiological hallmarks of a crushed finger with vascular compromise can be seen on the preoperative radiograms (longitudinal splitting, widening, and major displacement). (B) Bluish discoloration on the middle finger is evident. (C) The artery was exposed on one side and repaired. (D) Compare the color of the middle finger (arrow) in (B). (Copyright © 2015, Francisco del Piñal, MD.)

Fingers with vascular insufficiency should be immediately explored and revascularized because amputations have been reported. In most cases, repair of one of the digital arteries restores the flow and solves the problem.¹⁵

In the intermediate setting of a crushed finger, the skin envelope and/or the bone may be beyond repair. In the best case scenario, shattered cortical bone heals very slowly. By the same token, delayed bone healing has a major impact on ultimate digital function. At a minimum, comminuted phalangeal fractures require adding cancellous bone graft to speed up healing. Not infrequently, and despite fixation and bone grafting, healing might not occur. For such cases, a vascularized phalanx may solve the problem through a one-stage surgery.¹⁶ Bear in mind, however, that

some range of motion almost always will be lost. Furthermore, crush injuries in the area of the proximal phalanx can entail destruction of the pulley system. The authors have yet to find a satisfactory solution to this latter problem. Many of those cases end up with severe flexion contractures or amputation. Nevertheless, in select cases, the authors have had some success to this gloomy problem by transferring toes (**Fig. 15**).

In the authors' hands, major soft tissue loss of the fingers is best solved with the use of thin, pliable, free flaps. Their preferred free flaps for digital defect coverage are neurocutaneous flaps taken from the side of the toes, usually the tibial side of the second toe.¹⁷ Not only does this flap provide top soft tissue cover for fingers but also

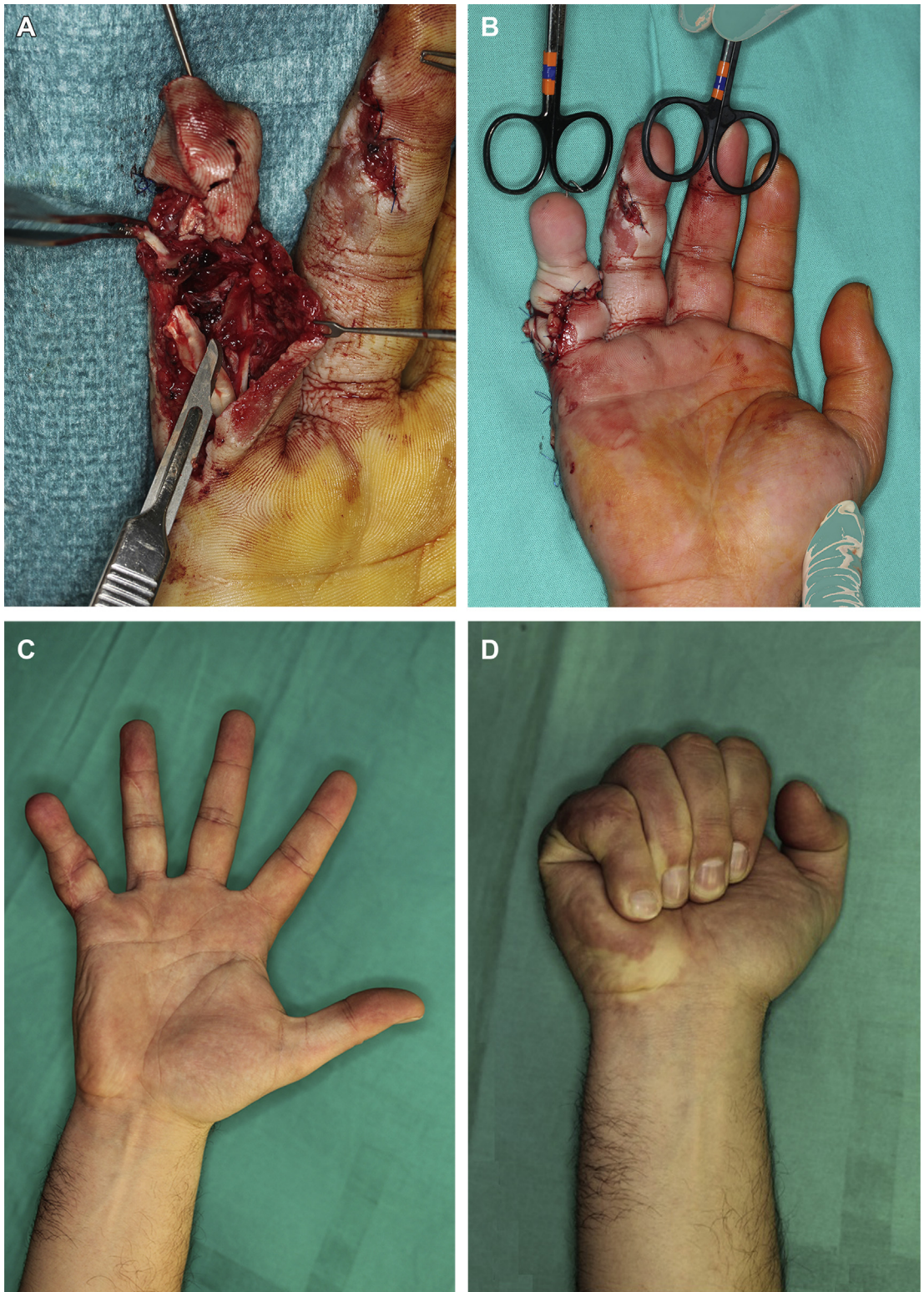


Fig. 15. (A) A crushed small finger in a young laborer. Note the extrusion of the flexor tendons from the pulley system. The PIP joint could be reconstructed. (B) A second toe transfer was performed 48 hours after the accident. (C, D) The result at 1 year. No other surgery has been performed, although aesthetic refinements have been scheduled. (Copyright © 2015, Francisco del Piñal, MD.)

provides a vascularized nerve and artery for flow-through reconstruction (**Fig. 16**).

In their most severe forms, crushed fingers have barely identifiable structures and are obviously beyond reconstruction. Apart from the possibility of replantation of some spare parts, the only other sound alternative is a free toe transfer. The authors recommend the liberal use of toe transfers in all patients, even in aged patients, provided they are fit and without serious comorbidities. This practice pattern is based on the positive experience of the senior author when toe transfers have been performed (through December of 2015, the senior author has done 420 toe-to-hand transfers with 3 failures).^{18,19} In cases where

a single finger is amputated proximal to the proximal interphalangeal (PIP) joint, the authors recommend ray amputation. This recommendation is based on 2 key facts. First, a replanted finger amputated proximal to the PIP joint does not yield a good functional result, at least in the senior author's experience. In fact, such replanted fingers ultimately become a burden to the rest of the hand. Second, no matter how long a second toe may be, it is still much shorter than a finger and moves poorly when transplanted to the hand. Therefore, the best indication for a single replant²⁰ (or a toe)²¹ is when the amputation is distal to the PIP joint. When more than one finger has been amputated, the goal of the surgical intervention is

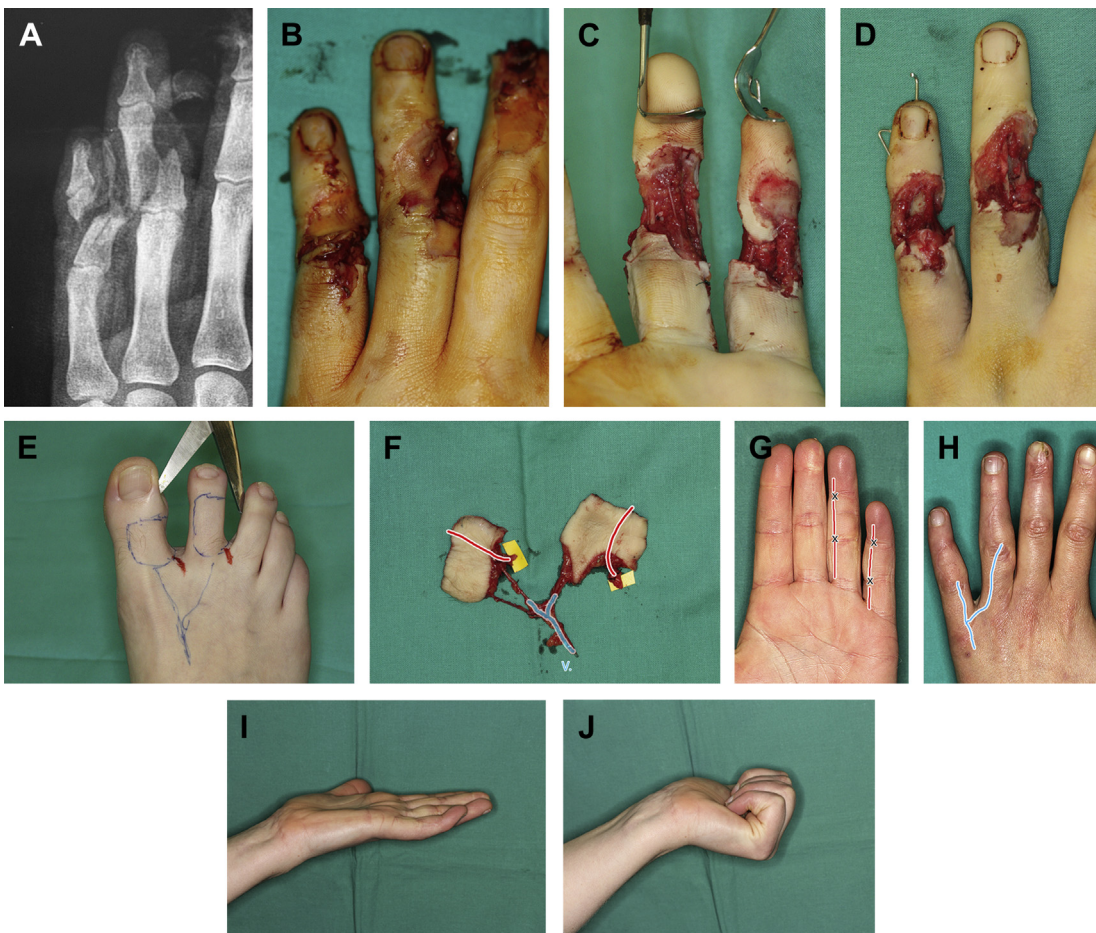


Fig. 16. This 22-year-old patient had her small and ring finger crushed by a sealing device, sustaining a combined thermal and crush injury. Because of the marginal blood supply to the digits, she was referred for treatment 48 hours after injury (**A**, **B**). The only inflow was through a small dorsal bridge shown here after debridement (**C**, **D**). Definitive fixation and re-establishment of the flow were performed in one stage using 2 digital flow-through free flaps (**E**–**H**). (**I**, **J**) Although her postoperative range of motion at the PIP was normal, to improve the active motion at the distal interphalangeal joint, tenolysis was performed. This eventually required the placement of a rod for rupture of the flexor digitorum profundus tendon of the small finger. The final results after all the procedures are shown. (Copyright © 2015, Francisco del Piñal, MD.)

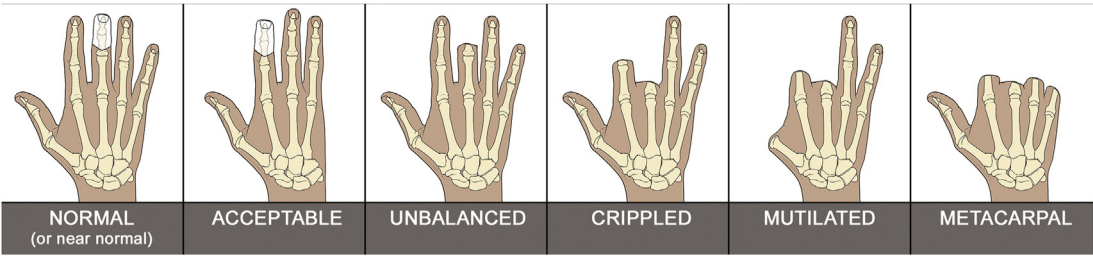


Fig. 17. Classification of finger injuries. In this sketch, the normal hand is roughly analogous to an unbalanced hand that has been improved with a second toe transfer. The acceptable hand is a crippled hand that is status post a toe transfer for the index finger and ray amputation of the middle finger. (Copyright 2015, Francisco del Pinal, MD.)

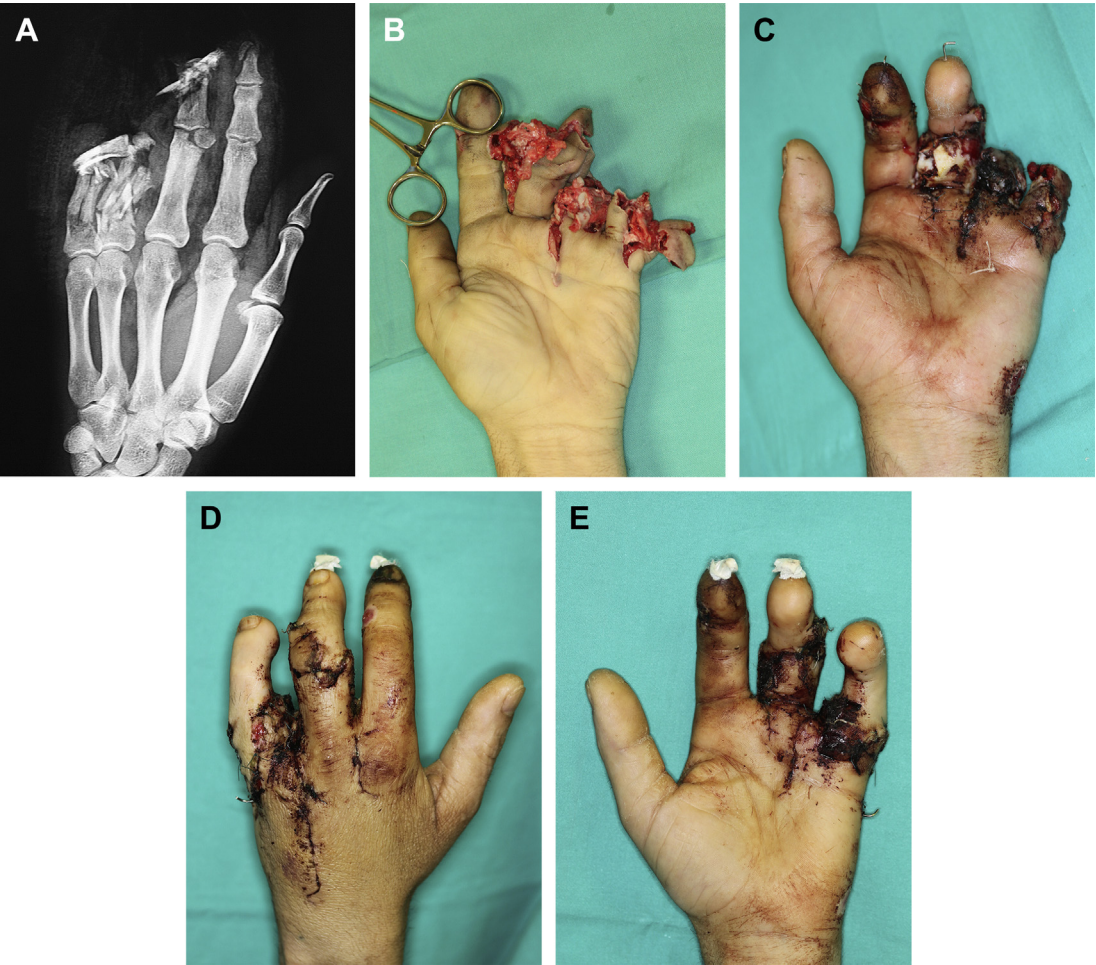


Fig. 18. This patient sustained a severe crush to his ulnar fingers. (A) The preoperative radiograms demonstrate longitudinal fractures from a crush. The fracture in the PIP joint of the middle finger was stabilized. (B) The pulleys are disrupted and the flexor tendons herniated. (C) Two days later, a second toe was transferred to the top of the base of the middle phalanx of the middle finger. (D, E) A week later (9 days after the injury), the contralateral second toe was transferred to the proximal phalanx of the small finger with a concomitant fourth ray amputation. The pictures shown are 16 days after the injury with all reconstructions done. (Copyright © 2015, Francisco del Piñal, MD.)

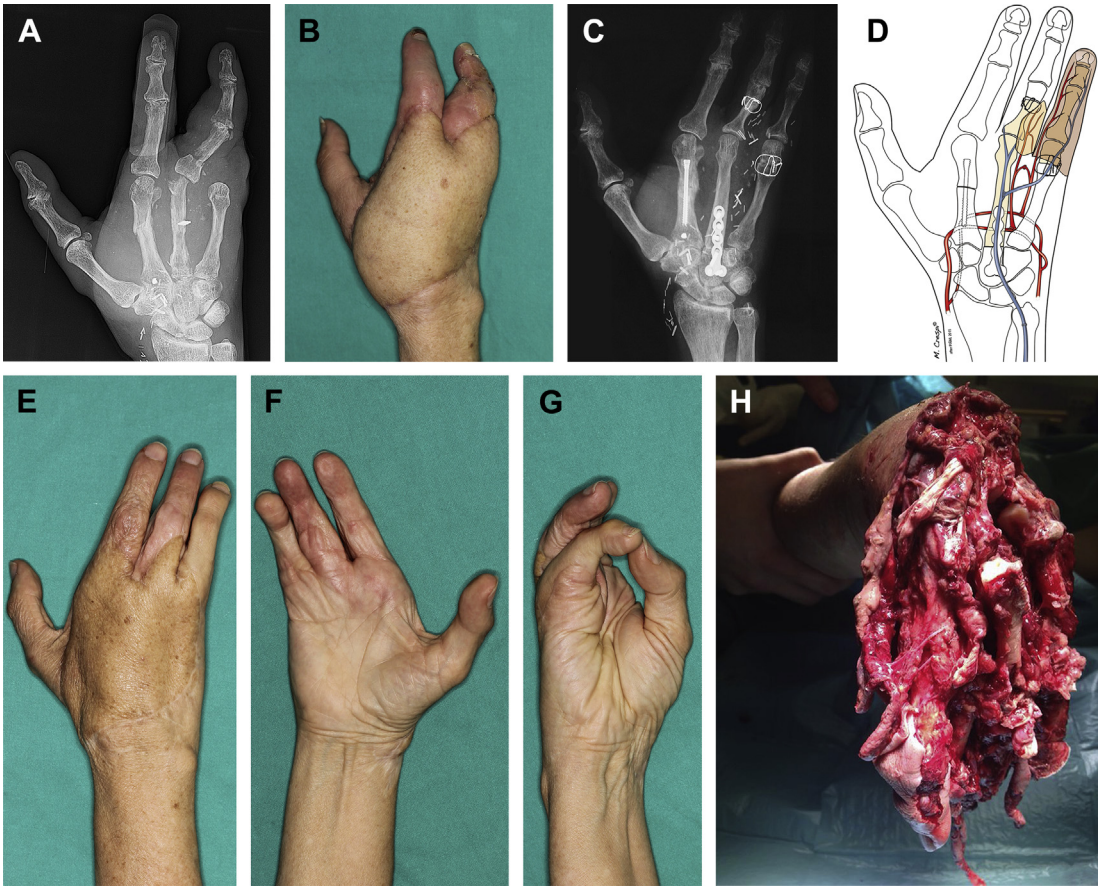


Fig. 19. (A, B) This 67-year-old patient had her hand trapped under a car. Initial surgery was performed elsewhere. Briefly, an anterolateral thigh flap was used for soft tissue coverage, together with transposition of the ring finger onto the third MP joint. The small finger was secondarily amputated. Furthermore, 7 additional surgical debridements for clearing deep infection were carried out over a 4-month period. Recommendation for amputation at the level of the distal forearm prompted the patient to seek a second opinion. The thumb had some motion, but the index and ring fingers had only sensibility preserved. The middle metacarpal and MP joint were found destroyed on the radiograms, with infection likely the cause. (C, D) The reconstruction was planned in 2 stages. At the first operation, the ulnar aspect of the ALT flap was thinned and the third metacarpal and MP joints, which were sequestered, were radically debrided. The second metatarsal and the corresponding metatarsophalangeal joint and the contralateral second toe were transplanted. In the second operation, some extensor tendons were reconstructed, and the radial part of the flap was thinned. No other surgery has been performed. (E–G) An aesthetically pleasing and basic functioning hand was achieved, thereby justifying the surgical effort. Interestingly, neither the patient nor her husband (himself a doctor, who caused the accident) was happy with the final outcome. It should also be stated that a series of ill-advised surgeries were performed during her initial care course. However, one has to admit that in some cases the nature of the original injury can overwhelm even an expert surgeon and the care initially provided was quite good (picture supplied by the original surgeon) (H). (Copyright © 2015, Francisco del Piñal, MD.)

to achieve anything close to the so-called acceptable hand. An acceptable hand has been defined as 1 with 3 fingers of near normal length, with near normal PIP joint motion, with good sensibility, with a functioning thumb. The term “acceptable hand” is so named because it is acceptable in both aesthetics and function (**Fig. 17**). By using toe transfers, lengthening procedures, finger

transpositions, and so forth, the surgeon can change a badly damaged hand into an acceptable one (**Fig. 18**).^{18,19,21}

MANAGEMENT OF LATE PRESENTING CASES

Here, the topic of late reconstruction will be lightly touched upon. It should be understood, however,

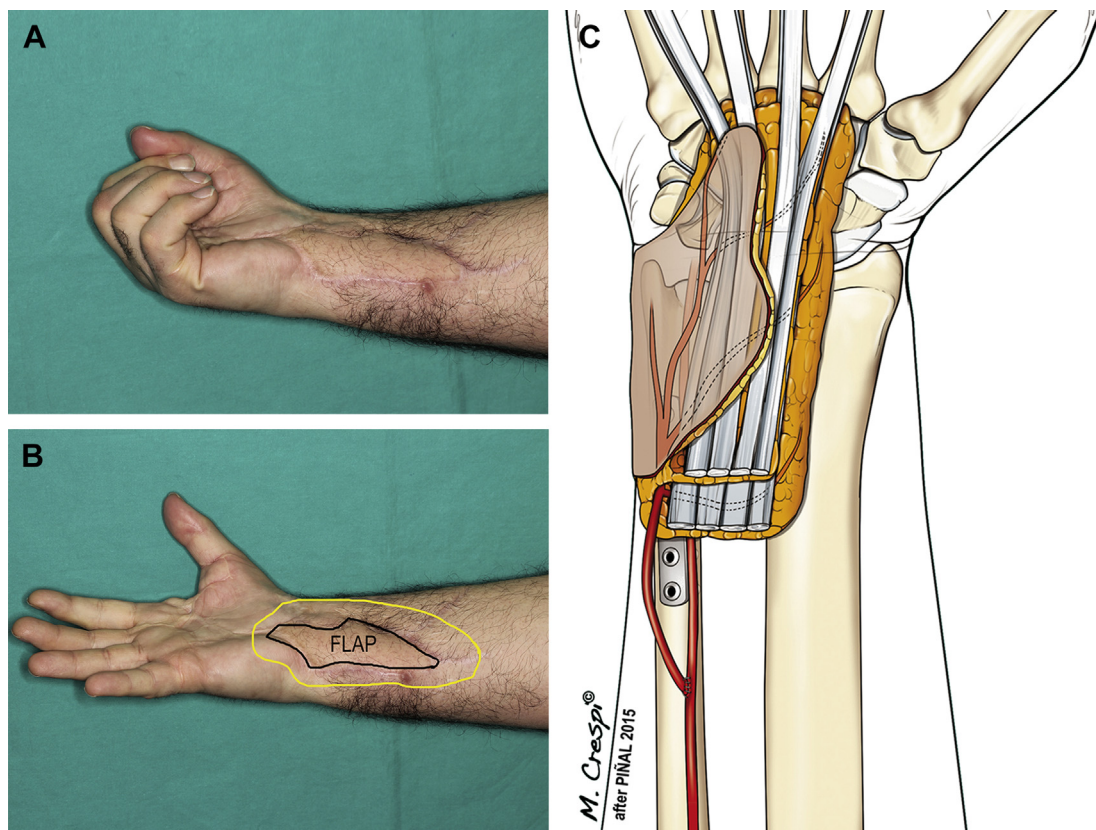


Fig. 20. (A, B) Flexion and extension obtained after multistage reconstruction of the patient shown in **Fig. 1**. The authors treated the malunion, excised scar tissue, and replace it with a well-vascularized free lateral arm flap, including an adipofascial extension (yellow) to encircle the flexor tendons, thus providing a better gliding environment. (C) Artistic rendering of the flap transfer. (Copyright © 2015, Francisco del Piñal, MD.)

that late reconstruction corresponds to the largest patient group in the senior author's practice. Late and very late referrals are unfortunately very common. To varying degrees, they all share the following characteristics: marginal vascular supply to the hand, poor soft tissue coverage, deep infection, malaligned and nonunited bones, and a disabling lack of motion, that is, a frozen hand sometimes in association with deep infection. If there is still something of use distally, then a reconstructive effort is warranted, but the result is never going to be as satisfactory as that expected with the reconstruction of an acute injury. The patient should be warned that in severe cases an assisting hand is the goal...; sometimes much more can be achieved, but this not always appreciated.

The "solution" is to think in reverse: debride, refix, revascularize, and recover. Toes and joints are liberally transferred to the injured hand in order to most closely approximate the "acceptable hand" (**Fig. 19**).^{18,19,21} A consistent finding in these cases is the lack of a gliding environment for

tendons and joints. The authors have had encouraging results by transferring vascularized adipofascial flaps (**Fig. 20**).¹⁴ In summary, the reconstructive effort can be enormous, and the results are never going to be as good as when these injuries are managed acutely, but still there is room to achieve acceptable function.

Five years have passed since our previous paper, and although the number of acute cases has diminished, partly due to a shift in my practice and partly due to prevention measures, I still see a number of subacute and chronic cases. Interestingly, as time goes by, they are much more difficult to treat as some of them have already had several operations and sophisticated surgery but somewhat haphazard, i.e. no road map existed, ending in an unsatisfactory result.

I consider there are some issues that are worth stressing, particularly in the chronic and subacute cases, as both the scenarios and the mistakes committed are recurrent. I have divided this into three items for discussion with examples.

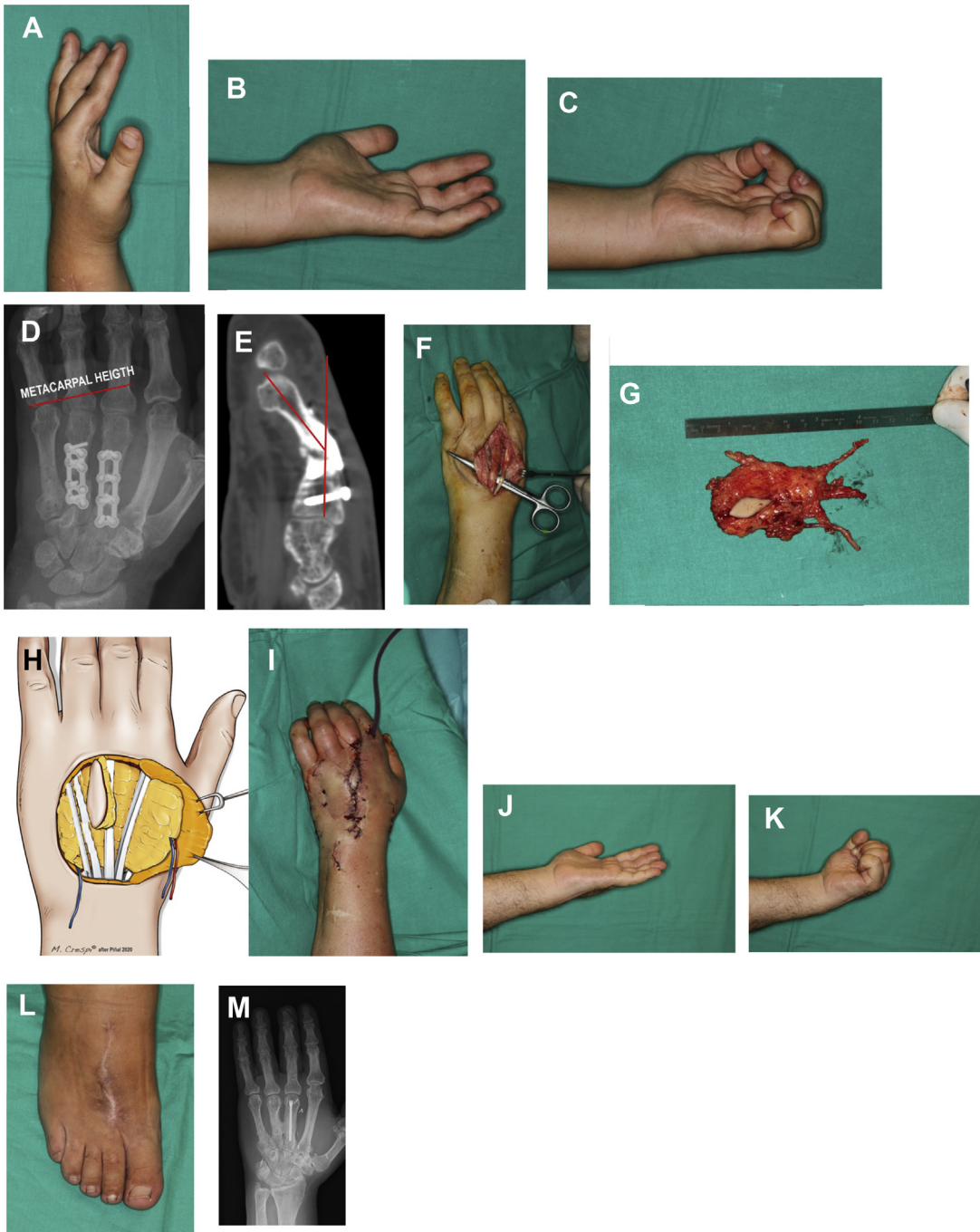


Fig. 21. Function at the time of “discharge” during the first consultation. (A-C) Maximum extension and flexion. Note that the MCP joints are stiff in extension. (D) Severe metacarpal shortening, with non-union and malalignment of the 3rd metacarpal (E). (D) Using the original dorsal incision the extensor tendons were released and capsulotomies were carried out in 2-4th MCP joints. (F) Dorsalis pedis fasciosubcutaneous flap, and setting in the bed (H-I). (J-M) Function, donor site and x-ray at 6 months.

EXHAUSTED BEDS

The first case seems very straightforward, but it is not. This young (42-year-old) patient sustained a crush to his hand nearly 2 years before

consultation. He had marked difficulties to achieve a fist and to open his hand fully, but he had been discharged as “terminated” result as shown in **Fig. 21A-C**. The patient was overweight (body

mass index of 35) but otherwise fit and very cooperative. In principle, the case called for the standard MPJ capsulotomies and extensor tenolysis, were it not for the fact that he had already been subjected to 4 attempts at achieving bony union and simultaneous capsulotomies and tenolysis. During the process, the 3rd and 4th metacarpals had become shortened, and even worst, the 3rd metacarpal was malangulated-nonunited (**Fig. 21D, E**). In summary, if we were going to repeat the same approach, we would not have succeeded.

Surgeon's frustration and lack of alternatives are common when handling severe injuries. This results in patients being abandoned to their fate, as occurred in the premature discharge of this particular patient. Such cases are crying out for a different approach.

This case, in fact, represents is a very common scenario, and highlights the importance of changing the environment for the tendons and the bone if one does not want to trip over the same stone as previous surgeons. It should be underlined that if the trauma were severe and/or much surgery had been performed, the healing potential of a given bed is nil. *Exhausted beds will never yield a good result; however, microsurgery allows providing well vascularized and pristine quality gliding tissue in one stage.* We have demonstrated that by transferring adipofascial flaps ("gliding flaps") the results after tenolysis in scarred beds are consistently good.¹⁴

Therefore, the case was planned for tenolysis, capsulotomies of the 2–4th MPJs, and a gliding flap (see **Fig. 21D**). At the same time correction of the malunited 3rd metacarpal was carried out. Achieving rigid fixation to permit immediate range of motion in a multi-plated bone is quite a feat. Contrarily, the intramedullary headless screw allows rigid fixation, skipping the problem of losing purchase in the multi-holed metacarpal. The choice of an adipofascial flap donor site in an overweight patient is also a problem. However, the dorsum of the foot is still thin in those individuals and for this reason a free dorsalis pedis fasciosubcutaneous flap was chosen.^{8,13} The flap was laid isolating the bone work and the devascularized bed from the released tendons (see **Fig. 21G, H**).

Immediate range of motion was begun, as well as the use of dynamic splints for metacarpophalangeal joint flexion. The result 6 months after the operation is shown (**Fig. 21I–M**).

SHODDY SURGERY PROVIDES A SHODDY RESULT

The next case has 2 parts, the first part (to follow) is the paradigm when conservative surgery and

delayed treatment are dispensed to a major injury. As we will discuss, several principles were infringed and this set the forearm in a pre-amputation status because of deep infection and nonunion.

This is exemplified by this 24-year-old patient who injured his hand and forearm in a motor-vehicle accident. The severity of the trauma should have made the surgeon aware that there was an enormous dead space to be filled, however, only the bones were fixed and the ragged skin was used to close the wounds (**Fig. 22A, B**). The wound was managed with dressing changes, exposing tendons that were lost (**Fig. 22C**). Eventually the soft tissue defect was covered with a dorsal rotation flap (**Fig. 22D**). This whole case was a comedy of errors, further aggravated by using a local flap. As a principle, local tissue should not be used, particularly if they have been undermined, as the risk of necrosis is high, as occurred here (**Fig. 22E**). Finally, a good cover was provided, with an anterolateral thigh flap, but this was done after several tendons had been lost and, much worse, a deep infection had already set in. *The surgeon should be one step ahead of the injury and not overawed by it.*

At this point, 3 months after the injury, the patient came for a second opinion. The hand was frozen (**Fig. 22G, H**) as was his wrist (flexion-extension 25°, pronation-supination 30°). Loosening of the hardware due to the infection was evident (**Fig. 22I**). I proposed removal of the hardware and a double-barrel fibula, but the patient and family declined for its being too aggressive. This view point was further supported by tertiary consultations that dismissed my approach as unnecessary "butchery".

Loosening of the hardware and/or a recent draining wound are tell-tale signs of a deep infection. However, the potent antibiotics may deceive temporarily the unwary. As a principle in severe injuries: if things look somewhat wrong, they sure are, since in the setting of a complex injury, complications are highly likely.

GLOBAL HAND SURGERY

Over the last years we have witnessed a very interesting phenomenon. On one hand, patients, thanks to internet, are more and more "knowledgeable" and, on the other, thanks to social networks, more and more demanding. A patient can contact another thousands of kilometers away and share their experience and outcomes. They share pictures, videos, experiences, and they come to the office knowing more than the head surgeon. This is good as this obliges us to sharpen

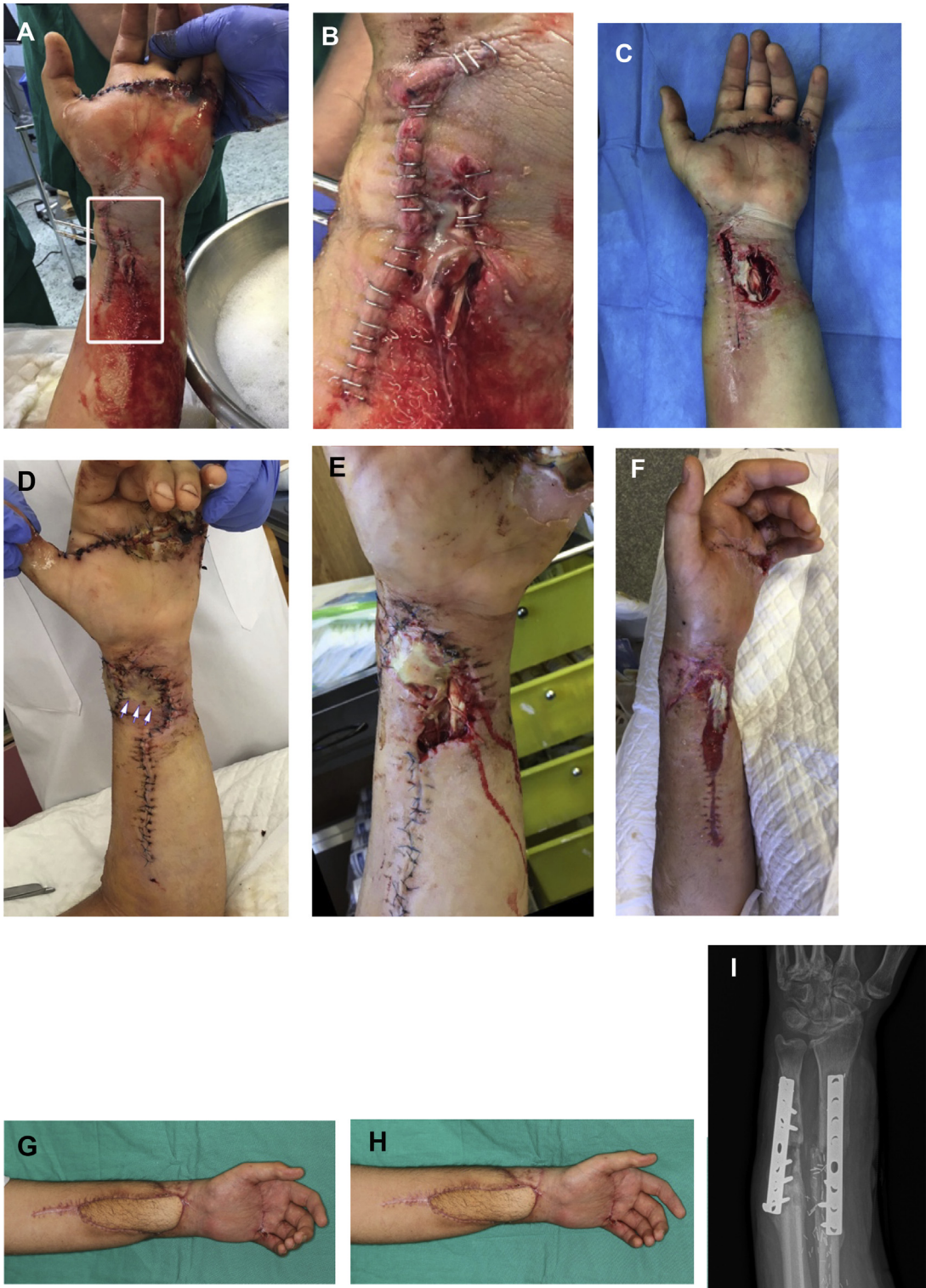

Fig. 22. (A) Initial closure, in the close-up view (B) the quality of the coverage can be envisaged: tendons are already exposed. (C) Necrotic tendons at 3 weeks. (D) In this early picture after a dorsal rotation flap necrosis is impending (arrows) and a week later evident (E). Definitive coverage was further delayed for 2 more weeks (G), before it was finally carried out (F). (G-H) At the time of the first visit the hand was completely frozen (the patient is attempting finger extension and flexion) and loosening of the hardware evident (I). (© Dr Piñal 2020.)

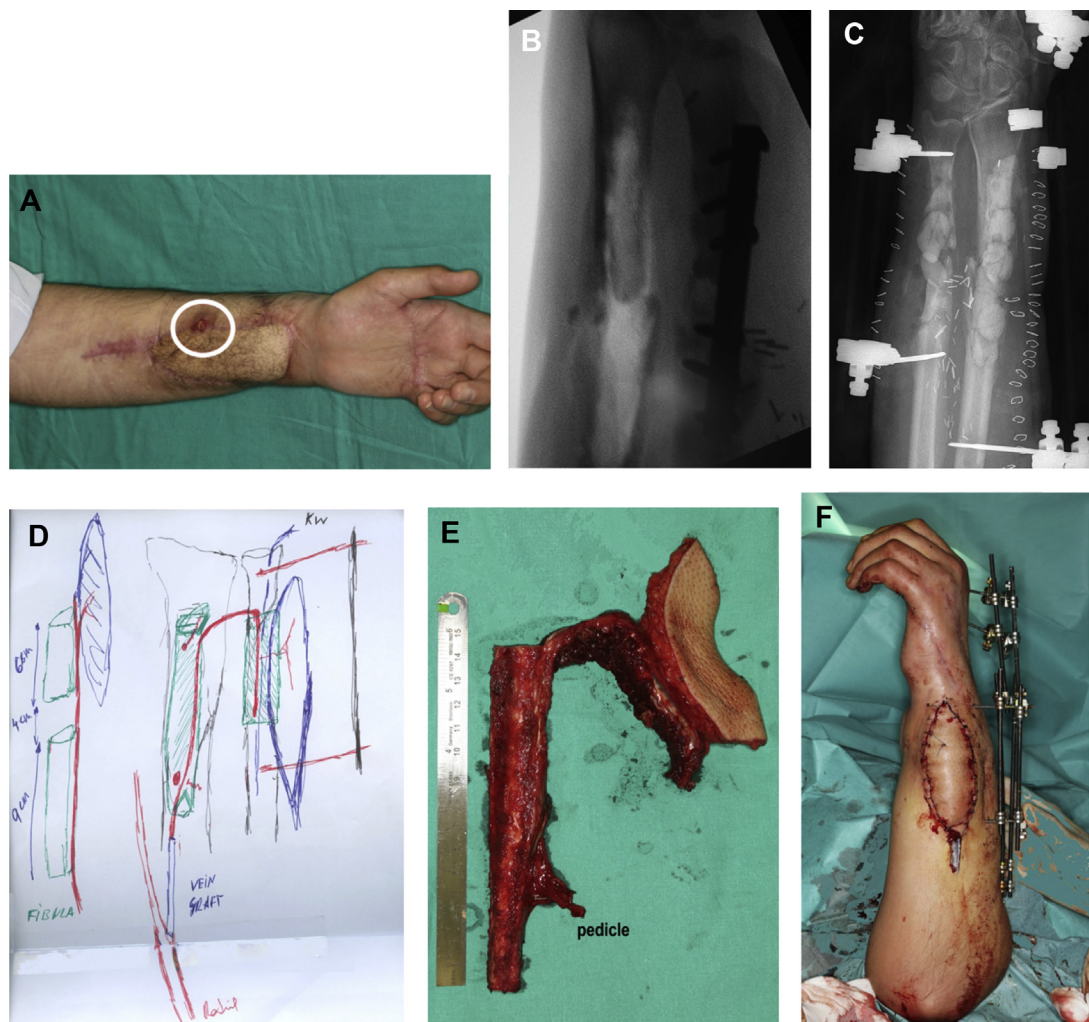


Fig. 23. (A) Status 5 months after the injury with a draining sinus (circle). (B) The radius and ulna were radically debrided and the antibiotic impregnated cement beads, acting as a spacer, were left for a week (C). (D) The sketch of the planned surgery and the corresponding fibula with the skin island in the distal bony segment (E). (F) Final view at surgery. Minimal internal fixation, in order to minimize devascularization, was reinforced maintaining the external fixator for a further 6 weeks. (© Dr Piñal 2020.)

the quality of our results, but by the same token, we are placed under much more stress. If we are not prepared to handle this new generation of knowledgeable patients, a constant confrontation will ensue, and the patient will be chronically unsatisfied. I think this is behind much of the current frustration, burnout, and early patient dismissal. Conversely, proper training and aggressive treatments in order to replace all lost tissue, benefit both patients and surgeons. Thus, it is paramount that the surgeon becomes proficient in all parts of hand surgery: classic hand, microsurgery, and arthroscopy, as otherwise the patient will not be given global treatment, and unhappiness will ensue.

Two months later (5 months after the injury), and after several ill-advised conservative approaches had failed, our patient returned with a fistulous track, but now ready and convinced of the need for a major reconstruction. The previously detailed plan was carried out: radical bone debridement, antibiotic impregnated cement spacer for a week, and a double-barrel fibula (Fig. 23)²². Were this deep infection problem not enough, the patient had 2 further unrecognized issues: a major one at the wrist level and a less important one at the metacarpals (Fig. 24A). In major trauma the surgeon has to prioritize, as the patient's resilience may not withstand prolonged reconstructive time-frames. This young economist, wanted to

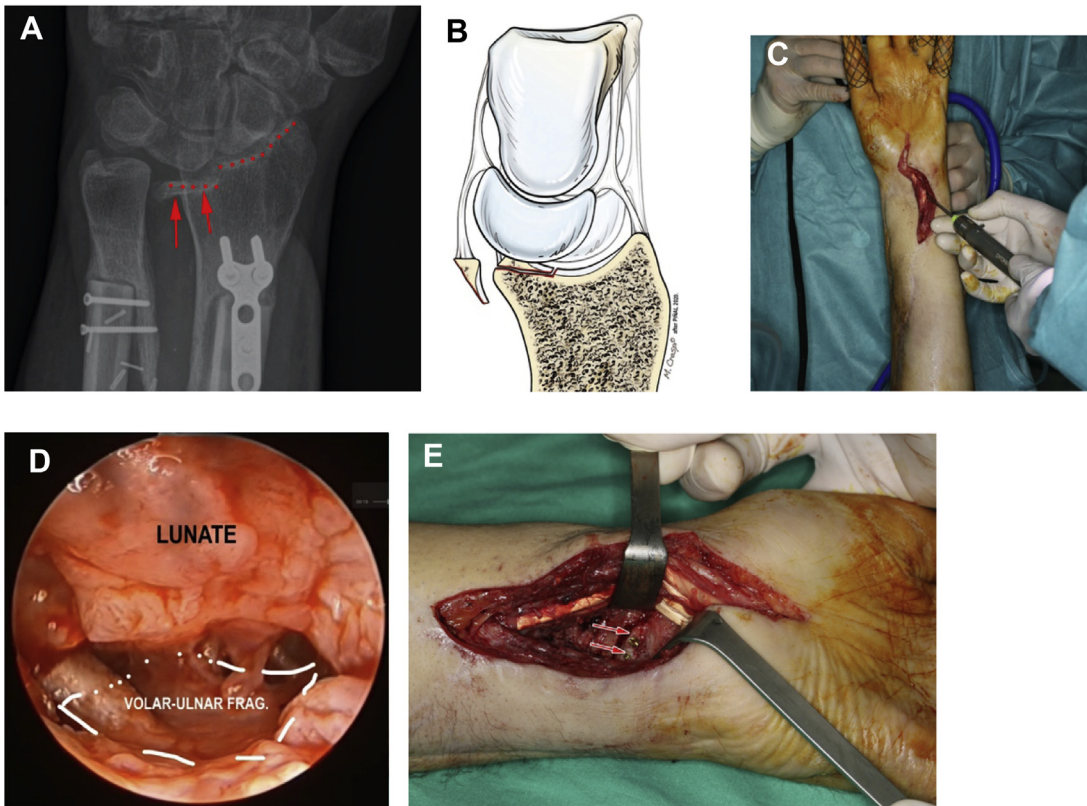


Fig. 24. (A) The fragment highlighted by an arrow. (B) Losing the volar-ulnar pillar of the radius causes volar and ulnar carpal translocation (Modified from reference 27) (C) Intraoperative view combining dry arthroscopy and open procedure. (D) Arthroscopic view of the volar-ulnar fragment reduced and (E) out-of-the-joint view of it being rigidly fixed with 2 screws. (© Dr Piñal 2020.)

start working as soon as possible and put this unfortunate accident behind him. Given that this upper limb was not going to have a full function, the fact that the joints in the carpometacarpal level were incongruent was thought to be secondary at this moment (as long as they caused no pain, they could be left untreated). Contrarily, the volar-ulnar fragment of the radius is crucial as when it fails it causes volar dislocation of the carpus, ulnar translocation and many times blocking of pronosupination (**Fig. 24B**).

Hence, once the risk of infection—cleared 6 months after the first stage—the radius malunion was addressed. I prefer arthroscopy to ascertain the proper reduction of any malaligned radius fragment.^{23–25} If the surgeon uses the dry technique during the operation,^{26,27} the advantages of arthroscopy (magnification, good lighting, and minimal invasiveness) can be combined with open procedures (**Fig. 24C–E**).

After a lot of effort on the patient's part and a complicated surgery, an acceptable result was obtained (**Fig. 25**). The message of this case is that

although salvage is possible, aggressive management in the first place would have shortened the recovery period, prevented complications, and provided a much better result.

In conclusion, crush injuries pose a phenomenal challenge when managed as emergencies and their treatment in the chronic stage requires a real feat of surgery. Reconstruction should follow a plan: first, get rid of the infection and second build a stable bony frame where motion is possible. It is paramount to be aggressive to clear infection and always add healthy rather than local damaged tissue. In my view, the only way to avoid bad results and the frustration this entails is by *preparation*. My final message is encapsulated perfectly in the words on the plaque in Dr Acland's laboratory which said: "Preparation is the only shortcut that you need".

SUMMARY

Crush injuries rate among the most feared injuries for hand surgeons. Stiffness, deep infection,

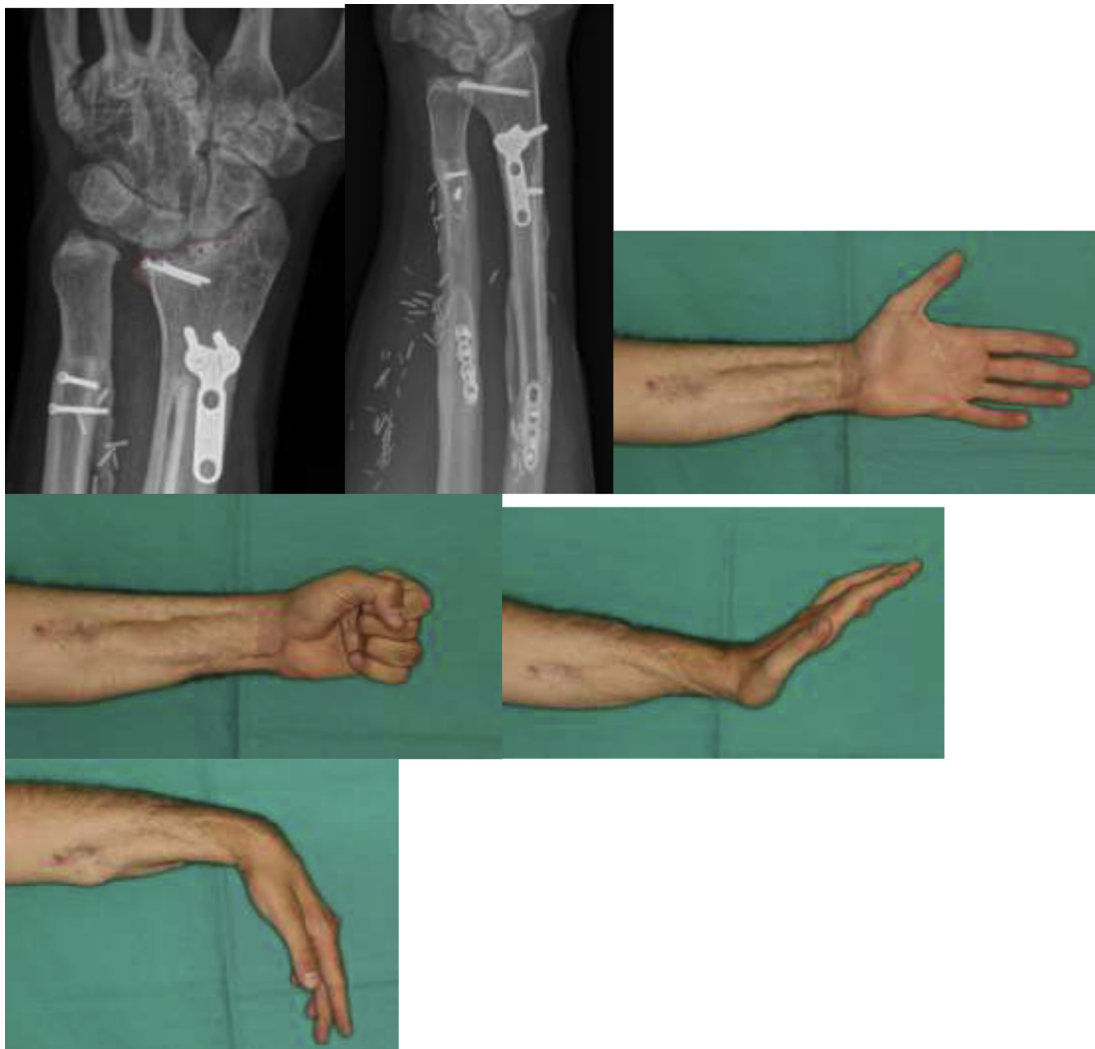


Fig. 25. The radiological and functional result 3 years after the reconstruction. (© Dr Piñal 2020.)

chronic pain, and late amputation are frequent outcomes. In the authors' experience, radical debridement of devitalized tissues, rigid fixation, and widespread usage of microsurgery to achieve rapid healing have dramatically altered the outcomes for this type of injury. In this work, the authors illustrate how adipofascial free flaps, along with free bone forming flaps, allow the surgeon to provide the ideal environment for healing. Toe transfers can dramatically improve function in digital defects.

REFERENCES

1. Del Piñal F. Editorial: I have a dream... reflex sympathetic dystrophy (RSD or complex regional pain syndrome—CRPS I) does not exist. *J Hand Surg Eur* 2013;38:595–7.
2. Del Piñal F, García-Bernal FJ, Delgado J. Is posttraumatic first web contracture avoidable? Prophylactic guidelines and treatment-oriented classification. *Plast Reconstr Surg* 2004;113:1855–60.
3. Weinzweig N, Starker I, Sharzer LA, et al. Revisitation of the vascular anatomy of the lumbrical and interosseous muscles. *Plast Reconstr Surg* 1997;99:785–90.
4. Del Piñal F, Herrero F, Jado E, et al. Acute hand compartment syndromes after closed crush: a reappraisal. *Plast Reconstr Surg* 2002;110:1232–9.
5. Herzberg G, Comtet JJ, Linscheid RL, et al. Perilunate dislocations and fracture-dislocations: a multicenter study. *J Hand Surg Am* 1993;18:768–79.

6. Del Piñal F, Pisani D, García-Bernal FJ, et al. Massive hand crush: the role of a free muscle flap to obliterate the dead space and to clear deep infection. *J Hand Surg Br* 2006;31:588–92.
7. del Piñal F, Moraleda E, Rúas JS, et al. Minimally invasive fixation of fractures of the phalanges and metacarpals with intramedullary cannulated headless compression screws. *J Hand Surg Am* 2015;40:692–700.
8. del Piñal F, García-Bernal FJ, Delgado J, et al. Overcoming soft-tissue deficiency in toe-to-hand transfer using a dorsalis pedis fasciosubcutaneous toe free flap: Surgical technique. *J Hand Surg Am* 2005;30:111–9.
9. Sakai K, Doi K, Kawai S. Free vascularized thin corticoperiosteal graft. *Plast Reconstr Surg* 1991;87:290–8.
10. Iorio ML, Masden DL, Higgins JP. Cutaneous angiosome territory of the medial femoral condyle osteocutaneous flap. *J Hand Surg Am* 2012;37:1033–41.
11. García-Elias M, Dobyns JH, Cooney WP 3rd, et al. Traumatic axial dislocations of the carpus. *J Hand Surg Am* 1989;14:446–57.
12. Shuck J, Masden DL. Options for revascularization: artery versus vein: technical considerations. *Hand Clin* 2015;31:85–92.
13. del Piñal F, Herrero F. Extensor digitorum brevis free flap: anatomic study and further clinical applications. *Plast Reconstr Surg* 2000;105:1347–56.
14. del Piñal F, Moraleda E, de Piero GH, et al. Outcomes of free adipofascial flaps combined with tenolysis in scarred beds. *J Hand Surg Am* 2014;39:269–79.
15. Reagan DS, Grundberg AB, Reagan JM. Digital artery damage associated with closed crush injuries. *J Hand Surg Br* 2002;27:374–7.
16. del Piñal F, García-Bernal FJ, Delgado J, et al. Vascularized bone blocks from the toe phalanx to solve complex intercalated defects in the fingers. *J Hand Surg Am* 2006;31:1075–82.
17. del Piñal F, García-Bernal FJ, Regalado J, et al. The tibial second toe vascularized neurocutaneous free flap for major digital nerve defects. *J Hand Surg Am* 2007;32:209–17.
18. del Piñal F. The indications for toe transfer after "minor" finger injuries. *J Hand Surg Br* 2004;29:120–9.
19. del Piñal F. Severe mutilating injuries to the hand: guidelines for organizing the chaos. *J Plast Reconstr Aesthet Surg* 2007;60:816–27.
20. May JW Jr, Toth BA, Gardner M. Digital replantation distal to the proximal interphalangeal joint. *J Hand Surg Am* 1982;7:161–6.
21. del Piñal F, Herrero F, García-Bernal FJ, et al. Minimizing impairment in laborers with finger losses distal to the proximal interphalangeal joint by second toe transfer. *Plast Reconstr Surg* 2003;112:1000–11.
22. Jones NF, Swartz WM, Mears DC, et al. The "double barrel" free vascularized fibular bone graft. *Plast Reconstr Surg* 1988;81:378–85.
23. del Piñal F, García-Bernal FJ, Delgado J, et al. Correction of malunited intra-articular distal radius fractures with an inside-out osteotomy technique. *J Hand Surg Am* 2006;31:1029–34.
24. del Piñal F, Clune J. Arthroscopic management of intra-articular malunion in fractures of the distal radius. *Hand Clin* 2017;33:669–75.
25. del Piñal F. Atlas of distal radius fractures. New York: Thieme; 2018.
26. del Piñal F, García-Bernal FJ, Pisani D, et al. Dry arthroscopy of the wrist: surgical technique. *J Hand Surg Am* 2007;32:119–23.
27. del Piñal F. Dry arthroscopy and its applications. *Hand Clin* 2011;27:335–45.