

An All-Inside Technique for Arthroscopic Suturing of the Volar Scapholunate Ligament

Francisco del Piñal, MD, PhD, Alexis Studer, MD, Carlos Thams, MD, Andrés Glasberg, MD

Repair of the volar scapholunate ligament has not been performed arthroscopically. We present an all-inside technique that presents closure of the anterior scapholunate interval. A Tuohy needle and a resorbable suture are all that is required. (*J Hand Surg* 2011;36A:2044–2046. Copyright © 2011 by the American Society for Surgery of the Hand. All rights reserved.)

Key words Arthroscopy, volar scapholunate ligament, suturing technique, wrist.

THE PALMAR ASPECT of the scapholunate (SL) interval is relatively inaccessible for open surgery because the volar extrinsic ligaments need to be severed before the SL ligament is reached. Consequently, with the exception of a few reports,^{1,2} most techniques for repairing chronic SL ruptures attempt to reinforce the dorsal SL, leaving the anterior part untreated. In partial injuries, some authors have shown promising results after arthroscopic debridement,^{3–5} highlighting the difficulty of reaching this area for repair. Even when using thermal shrinkage, this anterior portion is left untreated.^{6,7}

The purpose of this report was to present an arthroscopic technique that permits closure of the anterior SL interval by reefing the volar capsule and long radiolunate (LRL) ligament, and brings the SL ligament ends together. The technique is presented in detail.

SURGICAL TECHNIQUE

The ligament stumps are debrided with a synoviotome and the adjacent bony surfaces refreshed with a burr using the ulnar midcarpal (UMC) and radial midcarpal (RMC) portals. The scope is then positioned in the UMC portal to have an unimpeded view of the volar SL space, while the RMC is left free for instrumentation. A

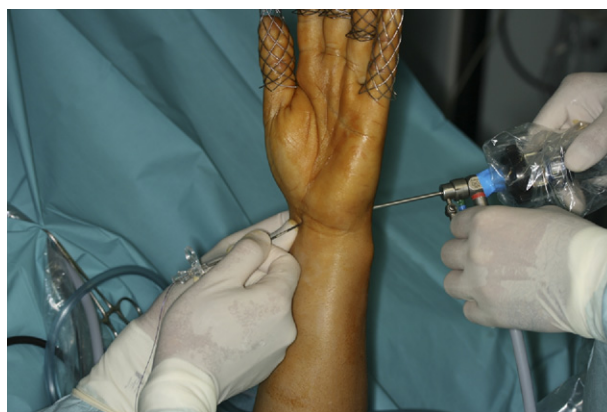

FIGURE 1: The Tuohy needle is inserted immediately ulnar to the FCR and 1 cm proximal to the distal wrist flexion crease while the assistant holds the camera in the ulnar midcarpal portal.

needle inserted immediately ulnar to the flexor carpi radialis (FCR) and about 1 cm proximal to the distal wrist crease will penetrate the joint in the vicinity of the SL space. Because this may require several attempts before the position is satisfactory, an intramuscular needle, which has a smaller bore than the Tuohy, may first be used to minimize local insult. Next, the Tuohy needle is inserted following the same path (Fig. 1).

The Tuohy needle is then loaded with a (colored) 2-0 polydioxanone thread, the end of which is retrieved with a grasper via the RMC portal and out of the joint (Fig. 2).

The needle is then withdrawn slightly under arthroscopic control, and once the tip of the needle has passed the volar capsule, it is slid on top of the capsule radially, reentering the joint distal to the anterior edge of the scaphoid. The thread is then pushed in

From the Instituto de Cirugía Plástica y de la Mano, Private Practice and Hospital Mutua Montañesa, Santander, Spain.

Received for publication December 15, 2010; accepted in revised form September 22, 2011.

No benefits in any form have been received or will be received related directly or indirectly to the subject of this article.

Corresponding author: Francisco del Piñal, MD, PhD, Calderón de la Barca 16-entlo, E-39002-Santander, Spain; e-mail: drpinal@drpinal.com.

0363-5023/11/36A12-0029\$36.00/0
doi:10.1016/j.jhssa.2011.09.021

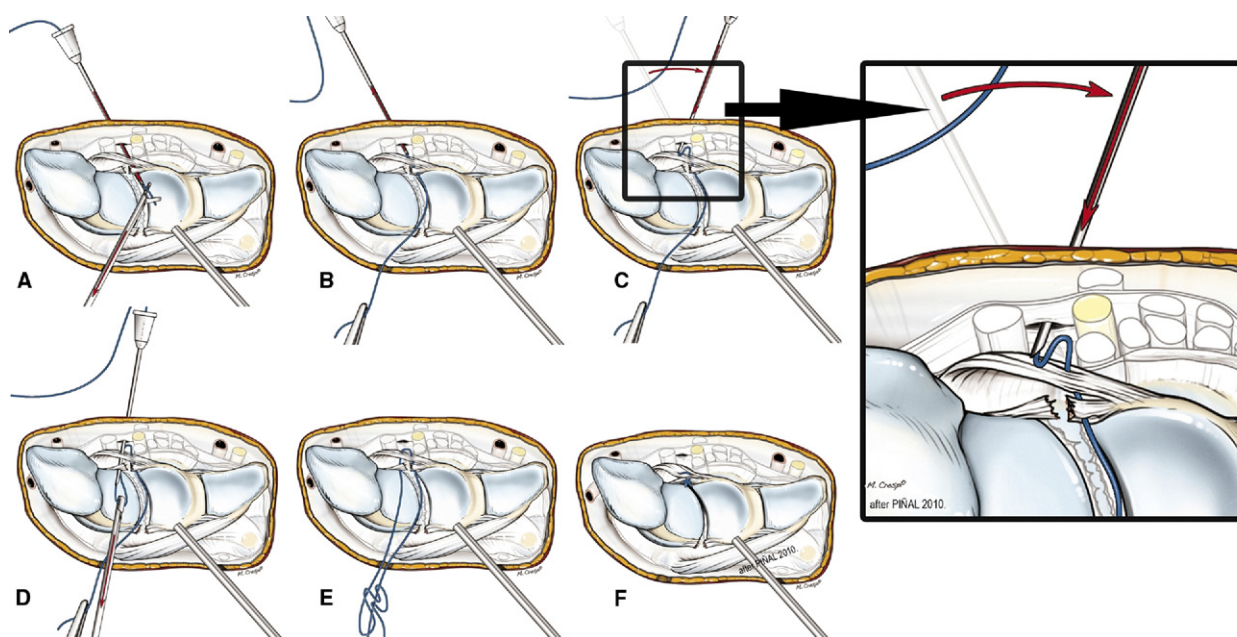


FIGURE 2: Steps of the operative procedure. The right side shows a close-up of the critical step of the needle slid over the anterior surface of the capsule.

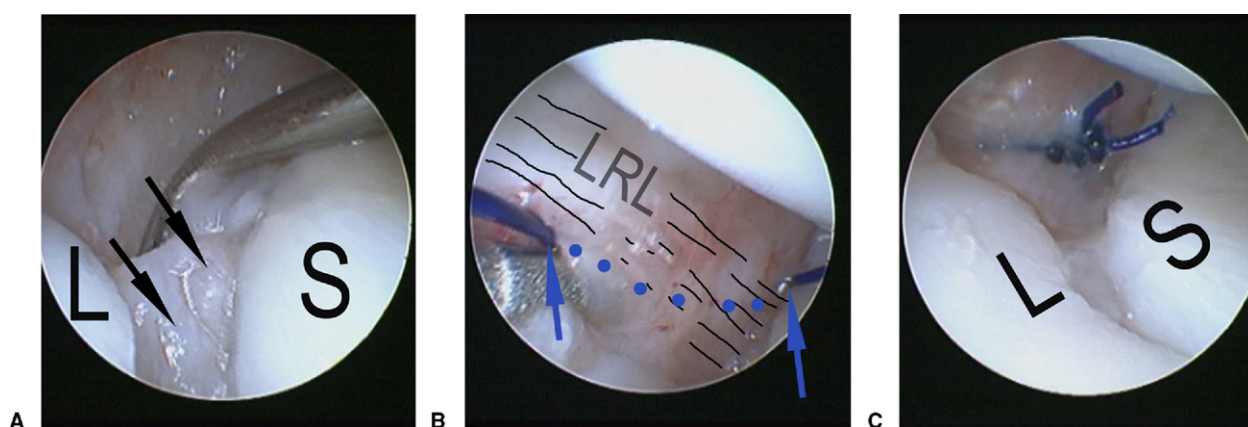


FIGURE 3: Intraoperative view of the operation in a clinical case (left wrist, scope in UMC portal). **A** Remnants of the SL ligaments (arrows) can be seen through the anterior SL gap. **B** The thread is seen passing volarly (marked in dots) from 1 side of the SL space to the other, including the capsule and the LRL ligament. **C** After the knot is tightened, the SL space is closed.

through the Tuohy needle, so as to have a loop inside the joint. Grabbing this loop with the grasper and pulling it out of the joint via the RMC will allow both ends of the thread to be outside the joint, while the hitch will be palmar to the capsule on both sides of the SL interval, including the LRL ligament. By performing a gliding knot, the throw will go all the way to the volar capsule. A knot pusher is then used to tighten the knot, bringing the volar aspects of the scaphoid and lunate together and closing the volar gap (Fig. 3).

It is crucial that both threads be pulled out of the joint through the same path in the RMC portal. If any tissue

is interposed, the gliding knot will be blocked on its way volarly. A suture hook can be used to make sure that both suture ends follow a single tunnel.⁸

DISCUSSION

The principle of this technique is similar to the all-inside procedure used for repairing dorsal tears of the triangular fibrocartilage⁸; however, it is applied to an area much more anatomically intricate. In fact, at first glance, the median nerve may be thought to be at risk when introducing the needle immediately ulnar to the FCR. Nevertheless, the nerve is always ulnar to the

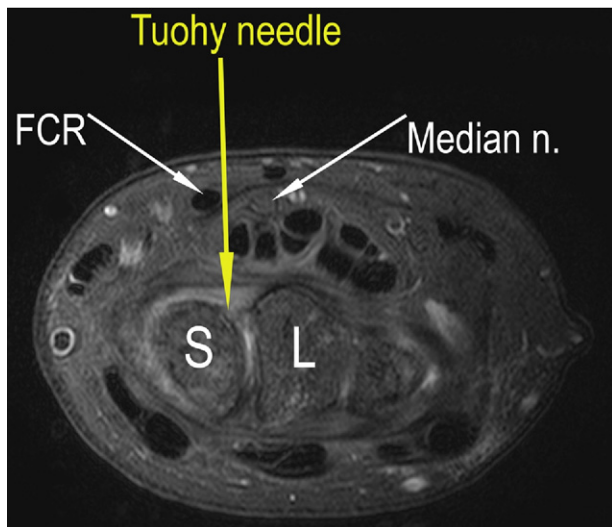


FIGURE 4: Magnetic resonance image at the corresponding level of the repair.

FCR, and this is evident in any axial MRI view at that level (Fig. 4). Nevertheless, a potential risk exists of injuring the palmar cutaneous branch of the median nerve. A 1-cm incision to clear the path of the Tuohy needle may be a safer alternative and may add minimal morbidity to the procedure. We have had no problem with the flexor pollicis longus, but if any doubt exists, the surgeon will rule out its entrapment by passively moving the thumb.

Our current experience with this procedure is limited to 4 patients who presented with different forms of ruptures, and with insufficient follow-up to draw meaningful conclusions. Our aim, however, was to present a technique that allows the remnants of the volar SL

ligament to be joined to the LRL with minimal scarring, to create a sort of capsulodesis. Despite the proximity of neurovascular structures, the procedure seems safe and harmless. It appears to be reasonable, although no benefits have been proved so far, to consider this procedure as a complement to dorsal SL ligament reconstruction with the classic procedures. By slightly modifying the technique, the procedure could be used to repair the dorsal part of the SL (Mathoulin et al, presented at the 11th Triennial Congress of the IFSSH, 2010: Book of abstracts EWAS02-01-05, 510) or to reef the volar capsule in case of midcarpal instability.

REFERENCES

1. Dunn MJ, Johnson C. Static scapholunate dissociation: a new reconstruction technique using a volar and dorsal approach in a cadaver model. *J Hand Surg* 2001;26A:749–754.
2. Marcuzzi A, Leti Acciaro A, Caserta G, Landi A. Ligamentous reconstruction of scapholunate dislocation through a double dorsal and palmar approach. *J Hand Surg* 2006;31B:445–449.
3. Ruch DS, Poehling GG. Arthroscopic management of partial scapholunate and lunotriquetral injuries of the wrist. *J Hand Surg* 1996;21A:412–417.
4. Weiss AP, Sachar K, Glowacki KA. Arthroscopic debridement alone for intercarpal ligament tears. *J Hand Surg* 1997;22A:344–349.
5. Abe Y, Katsube K, Tsue K, Doi K, Hattori Y. Arthroscopic diagnosis of partial scapholunate ligament tears as a cause of radial sided wrist pain in patients with inconclusive x-ray and MRI findings. *J Hand Surg* 2006;31B:419–425.
6. Hirsh L, Sodha S, Bozentka D, Monaghan B, Steinberg D, Beredjikian PK. Arthroscopic electrothermal collagen shrinkage for symptomatic laxity of the scapholunate interosseous ligament. *J Hand Surg* 2005;30B:643–647.
7. Shih JT, Lee HM. Monopolar radiofrequency electrothermal shrinkage of the scapholunate ligament. *Arthroscopy* 2006;22:553–557.
8. del Piñal F, García-Bernal FJ, Cagigal L, Studer A, Regalado J, Thams C. A technique for arthroscopic all-inside suturing in the wrist. *J Hand Surg* 2010;35B:475–479.