Extreme Thumb Losses: Reconstructive Strategies

Francisco del Piñal, M.D., Dr. Med.

Madrid and Santander, Spain

Background: Historically, complex amputations of the thumb have been managed in two stages and often require additional soft-tissue and tendon transfer for successful outcomes. This article provides several novel strategies to address these problems in a single stage using existing muscles, immediate free tissue transfer, and toe transfer.

Methods: From a personal experience of 482 toe transfers, 24 cases were performed to reconstruct extreme thumb losses. All thumbs were reconstructed in one stage. In only one case, the thumb was reconstructed with a second toe transfer; the remainder had a great toe (or a part of it) used for reconstruction. Suture, advancement, or tendon transfers were performed in all to restore intrinsic muscle function. In 19 cases, the web needed to be resurfaced with free (n = 18) or local (n = 1) flaps.

Results: All toes and flaps survived. Three patients required a secondary adductorplasty. Six of the seven patients with a metacarpal hand were able to perform tripod pinch. The rest had an average Kapandji opposition score of 7.5. Patients rated their functional and cosmetic result with a visual analogue scale score (ranging from 0 to 10) of 8.5 and 8.4, respectively.

Conclusions: In proximal thumb amputations, the surgeon should pay attention not only to the obvious thumb loss but also to the first web and the thenar muscles. The author recommends abandoning the standard approach of a pedicled groin flap followed by a toe. Otherwise, the thenar muscles become useless, the first metacarpal contracts, and the need for tendon transfers skyrockets. Further studies are required to compare the outcomes of these results to those of more classic transfers. (*Plast. Reconstr. Surg.* 144: 665, 2019.)

CLINICAL QUESTION/LEVEL OF EVIDECE: Therapeutic, IV.

4 THERAPEUTIC

There is a consensus that thumb amputations at or distal to the base of the proximal phalanx are better served with a toe transfer. Conversely, in more proximal amputations, and particularly if four fingers are present, the preferred method is pollicization.[1–6] Pollicization allows, in one-stage, an opposable neothumb without resorting to complex microsurgery. Pollicization, however, has the obvious disadvantage of losing a finger and providing only a slim neothumb. Furthermore, not all patients succeed in pinching or are satisfied.[1,4] To overcome this, Lin et al.[7] recommended osteoplastic reconstruction with a pedicled osteocutaneous groin flap followed by a toe transfer in a second stage.

The general recommendation for proximal thumb amputations in the setting of multiple-finger injuries is to provide abundant skin with a pedicled groin flap (with or without a bone graft)[2,5,6,8,9] and, after a maturation process of 3 to 6 months, to carry out a toe transfer. Sabapathy et al.[10] recommended, in very proximal amputations, the use of a second toe to have enough length of the metatarsal without running into foot problems if the hallux was to be harvested proximally, thus avoiding the need to include bone in the groin flap.

Our own experience in mutilated hand injuries[11] contradicts this step-by-step approach. We have had rewarding results using the hallux and carrying out the reconstruction in one stage. The

From private practice.
Received for publication July 12, 2018; accepted January 31, 2019.

DOI: 10.1097/PRS.0000000000005983

Disclosure: *The author has no financial interest to declare in relation to the content of this article.*

Related digital media are available in the full-text version of the article on www.PRSJournal.com.

key to success is to address the negative modifiers that are always present in proximal amputations, namely, web deficiencies and lack of thenar muscles. Indeed, a deficient web will not permit the thumb to move freely, and a muscle imbalance will convert a beautifully reconstructed thumb into a useless, collapsed digit.

Proximal thumb amputations are thus much more complex than "simply" a missing thumb. We have grouped these under the name of extreme thumb reconstruction (Fig. 1) because of their complexity. In an effort to evaluate immediate thumb reconstruction using one-stage reconstruction, we assessed 24 patients to see whether functional restoration of the thumb was possible in a single stage.

PATIENTS AND METHODS

From a consecutive experience of 482 toe-to-hand transfers (with three failures) performed by the author, 24 were considered extreme thumb reconstructions because they shared the following features: proximal amputations and/or first web defects and/or losses of the thenar/adductor muscles. The common denominator was the need for thumb reconstruction. No patient in the author's series with any of the above considerations was excluded from the study (Table 1). However, metacarpal hand reconstruction cases where only toes were transferred were excluded.

Fig. 1. This 22-year-old model (patient 20) was seen 4.5 months after being injured in a car accident. Despite a relatively benign amputation level (0.5 cm of the proximal phalanx), the lack of a first web space and the retraction of the short thumb muscles presented us with a phenomenal reconstructive challenge. (© Dr. del Piñal 2017.)

Except for referrals, most surgery was scheduled in the first week. When further surgery was required, the thumb was reconstructed first and the fingers 1 week later. This was planned to avoid reentering the previous operative field; thus, anastomoses were performed radially in the first operation and ulnarly in the second. To protect the previous transplant, 1500 U of heparin was injected before the tourniquet was inflated. Fingers were reconstructed aiming to obtain the so-called acceptable hand: one with three fingers of nearly normal length, with nearly normal proximal interphalangeal joint motion, and good sensibility, plus a functioning thumb.[11–13]

Our institution does not require institutional review board approval; however, procedures were performed in accordance with the Declaration of Helsinki of 1975 (2008 revision). All patients were cognizant about the treatment aims and understood the risks and possible benefits.

Surgical Technique

The hand was prepared first. Common to all types of extreme thumb reconstructions, the first metacarpal needed to be released from scar tissue. The flexor and extensor pollicis longus were dissected and mobilized until they had appropriate excursion. The latter was often avulsed and the extensor indicis proprius would be used for transfer. The remains of the short thumb muscles were mobilized. Because of their superficial location, the abductor pollicis brevis–opponens pollicis were often unusable, and had to be replaced by tendon transfers. However, dissection of the adductor pollicis from scarred tissue in the depths of the palm permitted its mobilization in many cases. In more severe instances, the adductor pollicis was released from the third metacarpal shaft, preserving its innervation, to permit its advancement. The aim was to reattach the native thumb muscles to the neothumb metacarpal or to the tendinous stumps of the toe's short muscles. Tendon transfers were performed primarily as needed to restore opposition, extension, or flexion. If the adductor pollicis was unusable, a Silastic (Dow Corning, Midland, Mich.) rod was placed in the intended path of the tendon transfer (Fig. 2), as

Table 1. Demographics of Extreme Thumb Reconstruction

Patient	Age (yr)	Time from Injury	Amputation Level	Lateral Thenar Muscles	Adductor Muscle	Web	Associated Injuries/Surgery
1 (Fig. 6)	43	5 days	Scaphoid	Absent	Absent	Absent	Carpal amputation
2	21	1 wk	Scaphoid	Absent	Absent	Absent	Metacarpal hand
3	48	13 mo	Scaphoid	Absent	Absent	Absent	Wrist fusion; flexor injury; PIO flap for cover
4	37	2 mo	M1 (0.5 cm)	Remains	Scarred	Absent	Radial digital nerve index
5	21	7 wk	M1 (1 cm)	Absent	Scarred	Absent	Isolated
6	53	2.5 mo	M1 (1 cm)	Remains	Scarred	Absent	Isolated
7 (Fig. 4)	26	4 wk	M1 (1.0 cm)	Remains	Scarred	Absent	Isolated
8	30	5 wk	M1 (1.0 cm)	Damaged	Scarred	Absent	Radial digital nerve index
9	31	3 days*	M1 (1.5 cm)	Absent	Absent	Absent	Metacarpal hand
10	44	14 days	M1 (2.0 cm)	Crushed	Crushed	Partial	Amputation 2–4
11 (Supplemental Digital Content 1)	33	4 days*	M1 (2.0 cm)	Crushed and severed	Crushed and severed	Partial	Amputation 2 and 3
12	28	16 days	M1 (2.0 cm)	Remains	Absent	Absent	Metacarpal hand
13	47	1 wk	M1 middle	Avulsion motor branch	Remains	Absent	Metacarpal hand
14 (Fig. 2)	23	5 days*	M1 middle	Absent	Absent	Absent	Radial nerve index
15	30	2 mo	M1 neck	Scarred	Scarred	Absent	Amputation index
16 (Fig. 5)	45	2.5 mo	M1 neck	Normal	Scarred	Normal	Amputation 2–4
17	51	2 mo	M1 neck	Normal	Scarred	Scarred	Amputation index at P1
18	47	5 days*	M1 head	Avulsed	Avulsed	Lacerations	Isolated
19	61	1 wk*	M1 head	Avulsed	Avulsed	Normal	Avulsion FPL/EPL; homolateral leg amputated (20 yr earlier)
20 (Figs. 1 and 8)	22	4 mo	P1 (0.5 cm)	Scarred	Scarred	Absent	Amputation 5; malunion second metacarpal
21	18	4 wk	P1 (0.5 cm)	Normal	Normal	Absent	Metacarpal hand
22	29	2 wk	P1 (1 cm)	Crushed	Crushed	Absent	Bilateral metacarpal hand
23	28	5 days	P1 (1 cm)	Normal	Severed	Absent	Radial nerve index/major soft-tissue defect
24	70	13 mo	P1 (1 cm)	Normal	Severed and scarred	Absent	Amputation 4 and 5; previous web release; frozen CMCJ

M1, first metacarpal; PIO, posterior interosseous; M, metacarpal; P1, proximal phalanx; FPL, flexor pollicis longus; EPL, extensor pollicis longus; CMCJ, first carpometacarpal joint.
*Initial care provided to these patients.

opposing function tendon transfers cannot be performed at the same time.

In eight cases, the thumb skeleton was restored by a "switching-two-toe transfer" (Fig. 3). This flap is composed of a trimmed-hallux[14] plus the second metatarsophalangeal joint and the second metatarsal bone (Fig. 2). The hallux is based on the peroneal digital artery, whereas the second metatarsophalangeal joint and the second metatarsal bone are based on branches from the distal communicating artery, and the tibial digital artery of the second toe distally. The distal second toe circulation is thus based on the remaining fibular digital artery, which should be carefully preserved. Proximally, the dissection stopped at the first dorsal metatarsal artery in five cases, the dorsalis pedis in one, and in the plantar vessels in two. One of the large dorsal veins was used as outflow.

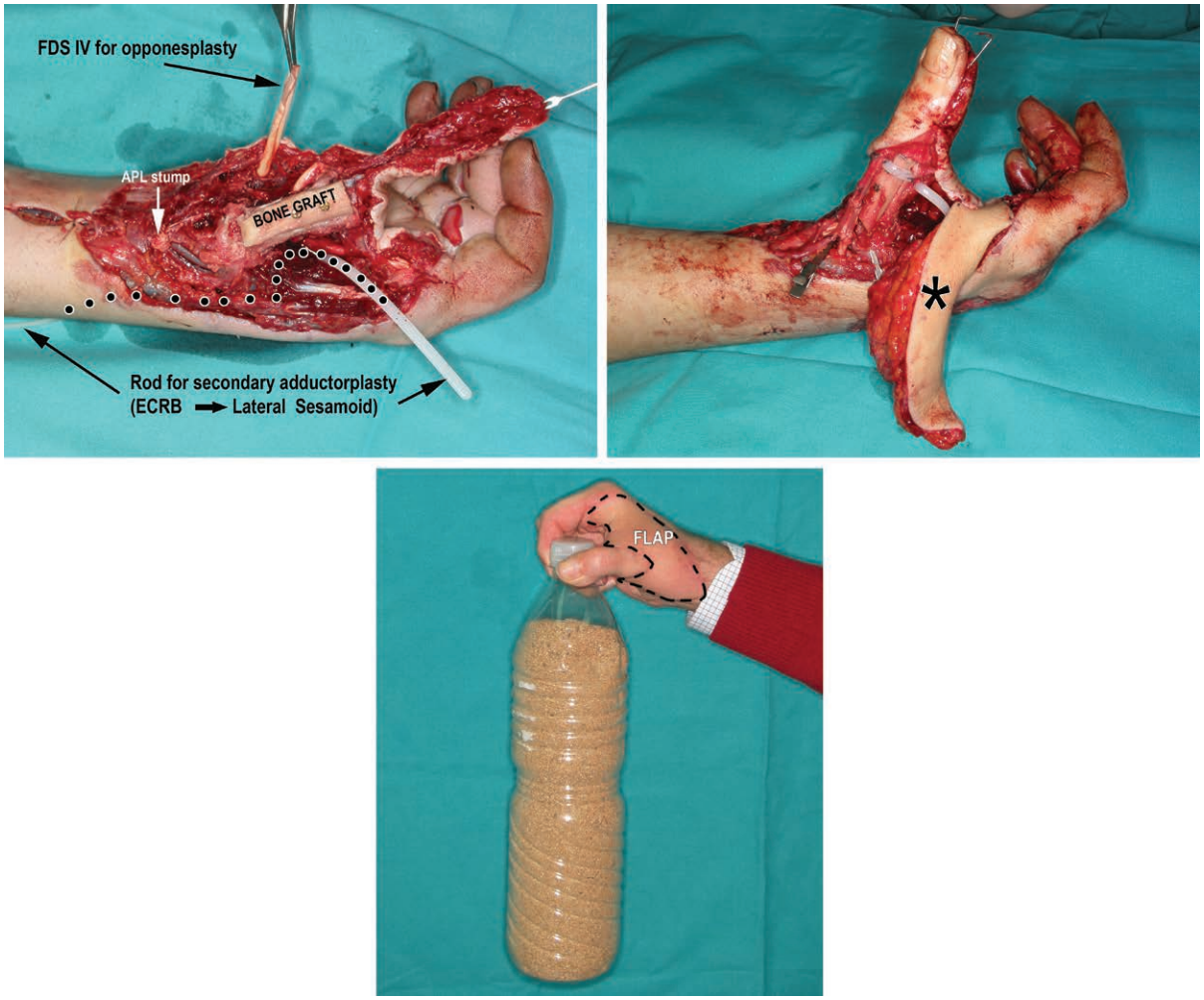

Fig. 2. (*Above*, *left*) This 23-year-old patient (patient 14) was trapped in a rolling hot press device, which caused charring of the thenar and first web muscles, which were débrided. Reconstruction was performed 72 hours later. The flexor digitorum superficialis (*FDS*) IV was retrieved distal to the carpal ligament and ulnar to the palmar fascia, which would act as the pulley for the opponensplasty as recommended by Royle-Thompson. A Silastic rod follows the path of the adductorplasty as recommended by Edgerton-Omer [modification of Smith transfer: extensor carpi radialis brevis (*ECRB*) through the third web space to abductor tubercle). The rod would be used in a second stage to guide a tendon graft and avoid dangerous dissection around vital nerves and vessels. The radial half of the carpometacarpal joint was lost. The abductor pollicis longus was reconstructed by an interposition tendon graft. A segment of nonvascularized humerus restored the dorsal two-thirds of the metacarpal. (© Dr. del Piñal 2018.) (*Above*, *right*) A tailored hallux is now in position. Coverage of the web, dorsum, and volar defects was achieved by splitting a lateral arm free flap (*asterisk*) between two perforators. Notice that the Silastic rod has been wound around the rebuilt first ray metacarpal to provide not only adduction but also pronation. (*Below*) The adductorplasty was carried out 6 months after the initial surgery. The patient is shown 1 year later. The bottle is full of sand and weighs approximately 3.5 kg.

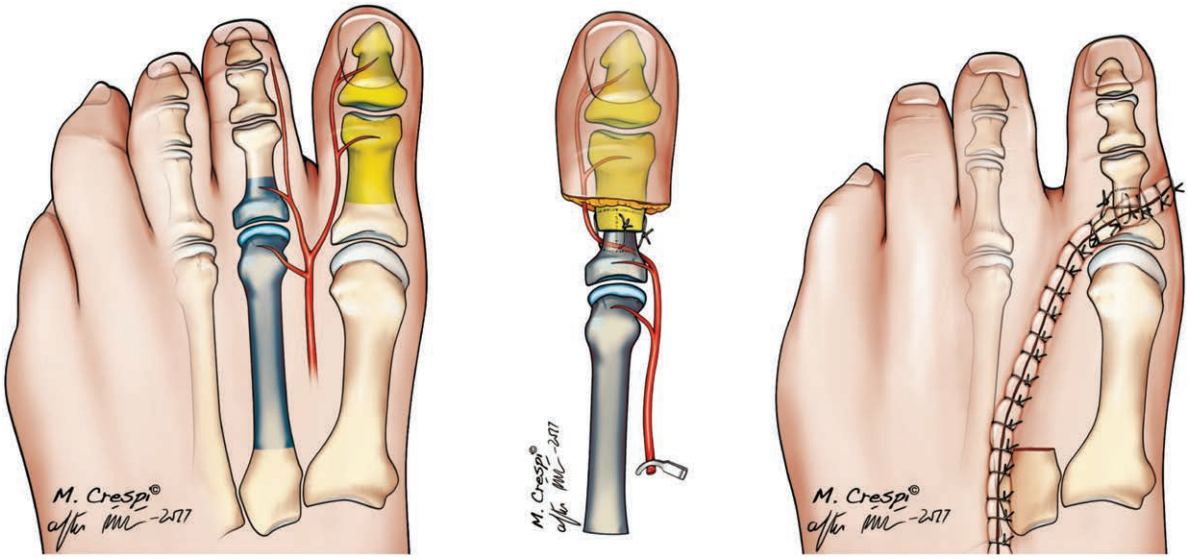

Fig. 3. Building of the neothumb with the technique proposed and the detail of the foot closure. Note that after switching the hallux onto the second metatarsophalangeal joint, the pedicle is located on the opposite side of the donor toe. (© Dr. del Piñal 2018.)

The "thumb" is built on a side table by switching the proximal phalanx of the hallux on top of the base of the proximal phalanx of the second toe. Fixation was performed with 90/90 wiring. The foot is closed as reported by del Piñal et al.[15] In all cases, there was a concomitant soft-tissue defect that included the web, which was treated in the same operation (Fig. 4).

In three cases where the thumb was amputated at the metacarpal head or more proximally, the index was coincidentally amputated but a part of the proximal phalanx remained. For those instances, the index metacarpophalangeal joint was transferred on the common digital arteries onto the first metacarpal, replacing the thumb metacarpophalangeal joint. On top of the index proximal phalanx, a minihallux was dissected[16] and the distal phalanx of the hallux fused to the proximal phalanx of the index. The operation differs very little from a classic index stump pollicization; however, at the time of dissection, a stump of 0.5 cm of the radial digital artery to the middle was included to provide a hooking point for the peroneal digital artery of the hallux. It is worthwhile stressing the importance of management of the short muscles in the hand. The thenar muscles were freed from surrounding scar and, if necessary, they were released partially from their origins, until they had an appropriate excursion. The abductor pollicis brevis–opponens pollicis was sutured to the tendon of the first dorsal interosseous, and the adductor pollicis was sutured to the first volar interosseous tendon. The stump of flexor profundus of the index (which was adhered to the digital canal in all cases) was sutured to the flexor pollicis longus when available or otherwise severed to avoid quadrigia. The flexor superficialis was always discarded. Similarly, the extensor digitorum communis was severed proximally and discarded, whereas the extensor indicis pollicis was sutured to the stump of the extensor pollicis longus if available or shortened if not. Mobilization was permitted after 4 weeks (Fig. 5).

Web defects are ideally reconstructed with the first or the second web from the foot if moderate in size. In this series, however, we only performed two web flap cases. The technique of foot web harvesting has been described elsewhere.[17] For larger defects, we have used several types of free flaps: gracilis, dorsalis pedis fasciosubcutaneous,[18] lateral arm, groin, and contralateral free radial forearm flow-through flaps, anastomosing distally to a trimmed-toe transfer (Table 2). In every case, utmost attention was paid to tailor the flap during insetting and to thin it if needed[19,20] to reproduce the native web and avoid excess tissue.

Assessment

In this heterogeneous group of patients, different goals were sought. In the metacarpal hands the basic hand, lateral pinch and tripod pinch were considered.[21] The Kapandji opposition score[7] was used as a grading system only for patients with normal fingers to oppose with the neothumb, as it is misleading if there are only toes. We also studied the way the patients perceived the

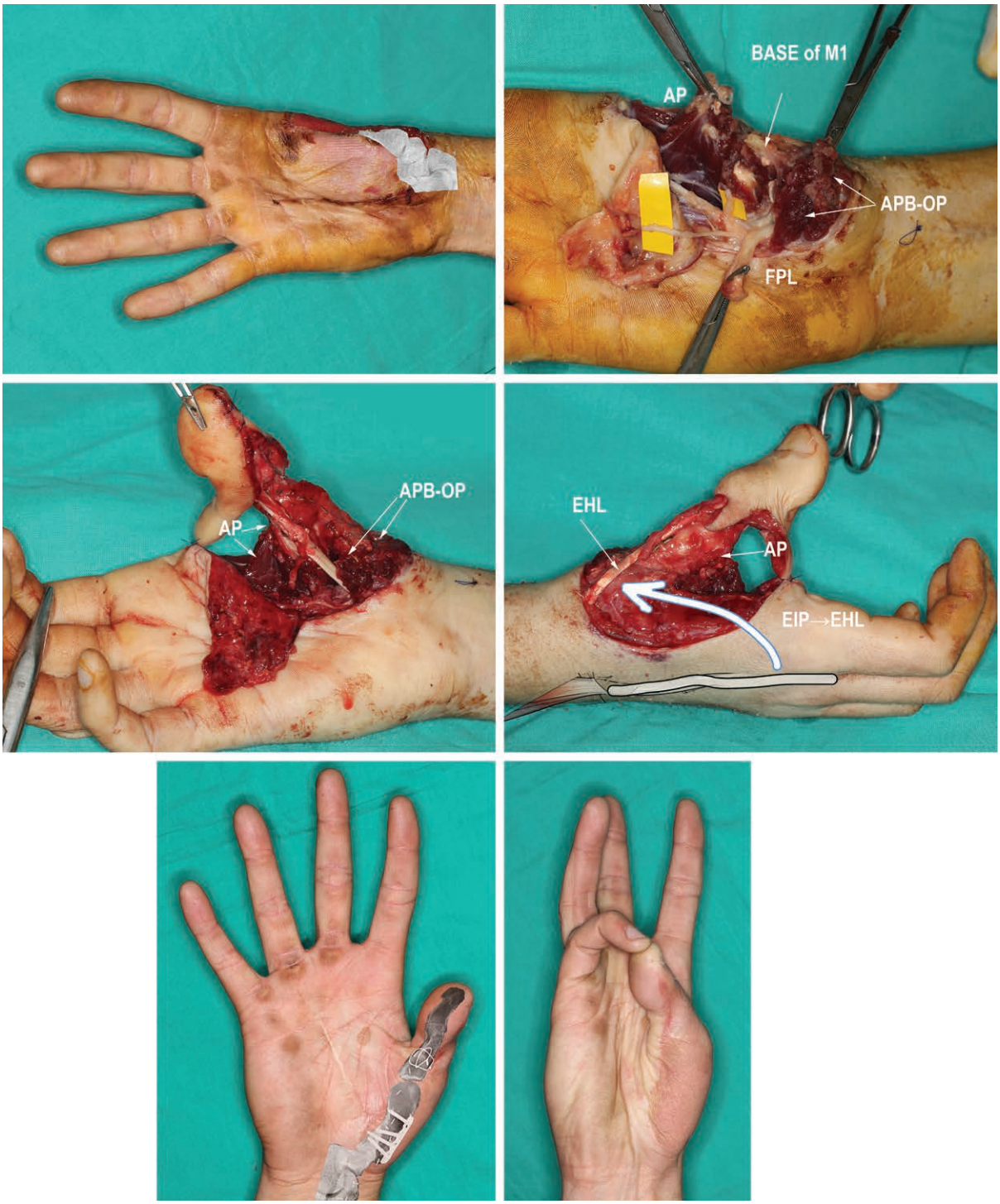

Fig. 4. This 27-year-old man (patient 7) came to consultation 4 weeks after sustaining an amputation at the base of the first metacarpal. The short thumb muscles were freed from scar tissue and advanced to their most distal position. The abductor pollicis brevis–opponens pollicis remains were sutured at the proximal third of the second metatarsal. The flexor pollicis longus was sutured to the flexor hallucis longus. The extensor pollicis longus had been avulsed and the extensor indicis proprius was used. Neither the extensor pollicis brevis nor a good short flexor muscle could be reconstructed. Eventually, an interphalangeal fusion was performed at 1 year. The result at 5 years is shown. *AP*, adductor pollicis; *APB-OB*, abductor pollicis brevis–opponens pollicis; *EHL*, extensor hallucis longus; *EIP*, extensor indicis proprius; *FHL*, flexor hallucis longus; *FPL*, flexor pollicis longus. (© Dr. del Piñal 2018.)

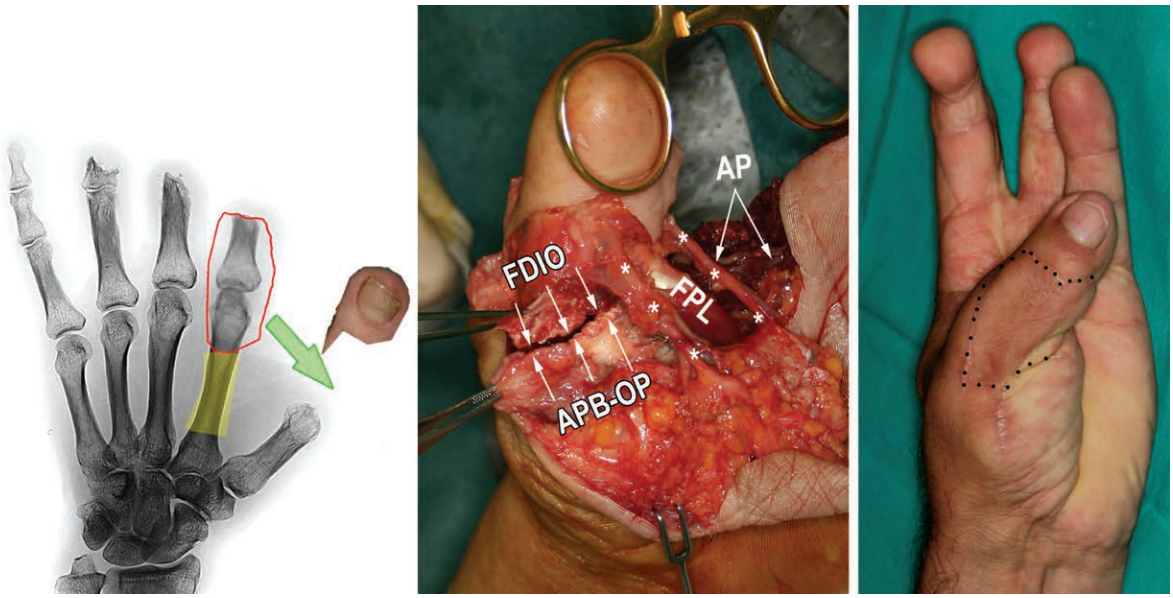

Fig. 5. In patient 16, the thumb was reconstructed and the web span restored in a single stage, by transferring a pedicled index metacarpophalangeal joint, resecting the proximal index ray amputation, and adding a minihallux (*left*). The scarred muscles have been mobilized and are ready for suturing to the tendons of the index stump. *AP*, adductor pollicis; *APB-OP*, abductor pollicis brevis–opponens pollicis; *FDIO*, first dorsal interosseous; *FPL*, flexor pollicis longus. The *asterisks* mark the neurovascular pedicles (*center*). Result at 5 years (reconstruction of the third and fourth fingers was carried out in one-stage by the contralateral second and third toes) (*right*). (© Dr. del Piñal 2018.)

reconstruction. They were asked about the subjective performance of their reconstruction and their cosmetic appraisal. This subset was graded using a visual analogue scale (10-point scale, where 0 = minimum and 10 = maximum).

RESULTS

Details of the procedures and the results are presented in Table 2. One iliac flap and a tandem second-to-third toe flap required reexploration. Eventually, all toe transfers and flaps were successful. Three patients had an adductorplasty by an extensor carpi radialis brevis to the lateral sesamoid 6 months after the operation (Fig. 2). Secondarily, two metacarpophalangeal joints and one interphalangeal joint in the reconstructed thumb needed to be fused. Minor procedures or tenolysis were required in five patients.

It is noteworthy that all patients with a metacarpal hand had basic pinch and were able to key pinch, and all but one were able to perform tripod pinch. Interestingly, the one patient who was unable to perform a tripod pinch had had an opponensplasty and an adductorplasty. The limitation was dependent on the stiffness in extension of the metacarpophalangeal joints of the fingers rather than the thumb itself. The average subjective ratings for function and cosmesis were 8.5 and 8.4, respectively.

DISCUSSION

Proximal Amputations

We are staunch advocates of Buncke's aphorism that "great toes make great thumbs," but in proximal amputations, harvesting a great toe with the metatarsal would lead to significant donor-site morbidity.[22,23] Pollicization, although popular for proximal amputations, procures an imperfect thumb and at times an unsatisfied patient.[1,2,4] For this reason, either the second toe[10] or an osteoplastic transfer, followed by a toe,[7] are the preferred options for some surgeons. The second toe is not, however, an ideal thumb replica, and has a small opposing surface, which is even more of a drawback if the damage is not isolated to the thumb. Likewise, osteoplastic reconstruction is not ideal either, and approximately half of the patients abandoned the reconstructive plan and did not have a toe transferred,[7] thus severely undermining the final result.

Since 2004,[15] we have been using a variation of the twisted-two-toe flap of Foucher,[24,25] permitting us to restore any length of thumb naming this "switching-two-toe transfer." The construct allows motion in the metacarpophalangeal and interphalangeal

Table 2. Procedures and Results

Patient	Procedure	Lateral Thenar	AP	Web	Other Procedures	Secondary Surgery	Tripod Pinch	KOS	Function	Cosmesis
1 (Fig. 6)	Second toe to radius	FDS to interosseous toe	—	Free groin	Tandem second and third toes (1 wk)	Flap debulking	Yes	NA	8	4
2	STTT to scaphoid	Extensor indicis proprius	—	PIO flap	Tandem second and third toes (1 wk)	FPL tenolysis	Yes	NA	9	8
3	STTT to trapezoid	Fused CMC	Fused CMC	Gracilis	FPL→EPL tenodesis	—	NA	5	9	10
4	STTT to M1	Advancement	AP origin release	Iliac	Nerve graft index	MCP fusion	NA	8	9	9
5	STTT to M1	Palmaris longus	Rod	Gracilis	—	ECRB→lateral sesamoid; MCP fusion	NA	7	5	7
6	STTT to M1	Advancement	AP origin release	Gracilis	—	—	NA	8	9	9
7 (Fig. 4)	STTT to M1	Advancement	AP advancement	Iliac	—	IP fusion	NA	8	10	10
8	STTT to M1	FDS IV	AP advancement	Iliac	Repair nerve; IP fusion	—	NA	8	8	9
9	Hallux to M1	Extensor indicis proprius	Rod	Gracilis	Tandem second and third toes (1 wk)	ECRB→lateral sesamoid; arthrolysis toes	No	NA	7	7
10	STTT to M1	Advancement	Advancement	DPFSC	Second and third toes 1 wk	—	NA	9	8.5	10
11 (Supplemental Digital Content 1)	Hallux to M1	Suture	Suture plus reinsertion	DPFSC	Second toe 1 wk	—	NA	8	9.5	10
12	Hallux to M1	Suture of remnants	—	Gracilis	Tandem second and third toes (1 wk)	—	Yes	NA	10	9
13	TTT to M1	Suture motor branch	Reinsertion	Gracilis	Tandem second and third toes (1 wk)	—	Yes	NA	6	7
14 (Fig. 2)	Hallux to M1	FDS IV	Rod	Lateral arm	Bone graft; nerve graft index	ECRB→lateral sesamoid; Z-plasties palm	NA	7	8	8.5
15	Second MCPJ plus minihallux	Advancement	AP origin release	—	—	—	NA	7	8	9
16 (Fig. 5)	Second MCPJ plus minihallux	Advancement	AP origin release	—	Second and third toe transfer 3 mo	Pulp plasty second and third toes	NA	9	10	9
17	Second MCPJ plus minihallux	Advancement	Advancement	—	—	—	NA	9	10	10
18	Hallux to M1	Advancement	AP origin release	—	—	Z-plasties in web; pulp plasty	NA	9	9,5	10
19	Hallux to M1	Advancement	AP origin release	—	FHL reinsertion in muscle	Pulp plasty	NA	7	9	10
20 (Figs. 1 and 8)	TTT to P1	FDS V	Massive scar excision; AP origin release	Fourth web; flow-through flap	Fourth finger→fifth metacarpal	—	NA	7	9	9
21	TTT to P1	NN	NN	DPFSC	Tandem second and third toes (1 wk)	—	Yes	NA	8	5
22	Triple toe transfer	Scar release	AP fascia release	Gracilis	Surgery contralateral hand	—	Yes	NA	6	7
23	TTT to P1	NN	Suture	Radial forearm flow-through flap	None	—	NA	9	10	10
24	Mini-hallux plus trapezium interposition	NN	Massive scar excision; AP origin release	Second web foot; flow-through flap	CMC joint arthroplasty	—	NA	4	8	8

AP, adductor pollicis; KOS, Kapandji opposition score; STTT, switching-two-toe transfer; PIO, posterior interosseous; FPL, flexor pollicis longus; NA, not applicable; CMC, first carpometacarpal; EPL, extensor pollicis longus; M1, first metacarpal; MCPJ, metacarpophalangeal joint; ECRB, extensor carpi radialis brevis; IP, interphalangeal; FDS, flexor digitorum superficialis; DPFSC, dorsalis pedis fasciosubcutaneous; FHL, flexor hallucis longus; NN, not needed; TTT, trimmed toe transfer.

joints, although often one of these joints requires fusion (see below). The main advantages, however, are that a closer thumb replica is obtained at the hand, without endangering the foot.

There are some very important technical considerations at the time of carrying out this operation. First, in this modification, there should not be a twisting motion, but a switch of the hallux on top of the proximal phalanx of the second toe. For this to take place, a sufficient length of peroneal digital artery of the hallux has to be dissected free to prevent vessel tension. Second, this switching will place the donor artery on the contralateral side. In other words, the homolateral hallux will set the donor artery radially and not in the web as would be expected. This is important at the time of the anastomoses. Finally, the metatarsophalangeal joint should not be reversed to increase the range of motion, as this creates sidewise instability at the time of pinching.[26] In our two earliest cases, we had to solve this secondarily by metatarsophalangeal joint arthrodesis.

In instances where the thumb and the index finger are amputated such as in radial-oriented amputations,[11,27] the benefits of pollicization of the index combined with a minihallux are multiple: the first web is increased, the requirements from the foot are minimized and, most importantly, a functional joint is added.

In cases where the carpometacarpal joint is missing, the chances of having a normally functioning thumb are limited. Experience in the literature is scarce. Pollicization of the healthy index provides only some function if there were normal short muscles present.[1,2,4,28] Sabapathy et al.[10] and others[29,30] recommended a second toe when there is more than one finger amputated. Function was satisfactory, although they admitted clawing of the transferred toe, which is a problem that can be prevented with appropriate motorization when available.[31] In one of our cases, where the rest of the fingers were preserved, it was managed with a switching-two-toe transfer plus gracilis, and was motorized as in a tetraplegic thumb (see below). In another case, a carpal amputation, we used a second toe for the thumb, and a tandem-toe for the ulnar part of the joint. This is the only case where a second toe was used in the author's whole experience. A tripod pinch was achieved and proved to be a good alternative to avoid the problems of hand transplantation (Fig. 6).[31]

Fig. 6. Patient 1. (*Left*) Degloving of skin proximal to the proximal wrist crease was managed by a pedicled groin flap elsewhere. Five days later, the hand was detached and the axial vessels of the groin flap were dissected and used to cover a second toe implanted in the radius (it was not the ideal flap but was still a valuable piece of tissue). (*Right*) One week later, tandem second and third toes were planted on the lunate and the scaphoid. A pinch opening of 4.5 cm and full closure was achieved. The pinch was 7 kg (note that, apart from the long flexor and extensor to the corresponding tendons in the hand, one flexor superficialis was sutured to an intrinsic tendon of each toe to prevent a claw deformity). (© Dr. del Piñal 2018.)

Short Muscles

Lin et al. have demonstrated the importance of providing an opponensplasty to improve the quality of pinching in proximal thumb amputations.[7,21] Although this approach may be valid in unsophisticated reconstructions, such as a metacarpal hand, it will not work if we are striving for a "normal" thumb. This should not be a surprise to the reader: a normal thumb needs seven tendons to control the three thumb joints. If there are fewer, such as in paralytic conditions, collapse and Z-deformity will occur. There is no reason to think that a reconstructed thumb will behave differently. Thus, at the time of reconstruction, the surgeon has to judiciously use arthrodesis and transfer of available motors to prevent a useless neothumb. The combinations are uncountable, as the scenarios are rarely repeatable. Several options have been presented in Table 2 and general ideas are presented in Figure 7.

The management is, in any case, beyond the scope of this article, but is based on the approach to the tetraplegic thumb[32,33] and also the management of the complex paralytic thumb.[34] Saying this, we have found that the only way of achieving a "normal" functioning thumb is by preserving the original intrinsic muscles. Staging reconstructions will render the muscles unsalvageable and will skyrocket the need for transferring tendons,[7,21] which may not be available. This is, without doubt, the main advantage of immediate reconstruction and has not been sufficiently stressed in the literature: delaying the reconstruction will entail functional loss of the important short muscles. [**See Figure, Supplemental Digital Content 1**, which shows that despite the severity of the crush in the thenar and first web muscles, restoration of the metacarpal length and suturing of the ragged muscles prevented muscle scarring in a shortened position (*above*). Once the swelling began to fade at 5 days (*inset*), the thumb and web were reconstructed. One week later, a second toe was planted in the middle finger stump. (*Below*) Result at 15 years highlights the importance of immediate reconstruction for keeping the function of the short muscles (case 11) (© Dr. del Piñal 2018), ***http://links.lww.com/PRS/D647***.]

Web

Because of its triangular shape, lack of just 1 cm of skin in the web severely impairs the ability of the thumb to grab large objects. A soft-tissue defect at the web is a constant feature in major amputations. Furthermore, edema and scar tissue will drag the first metacarpal ulnarly, and in a matter of months the adductor pollicis muscle will become irreversibly contracted. We stressed the importance of using progressive splinting to prevent this from occurring,[35] but using first web

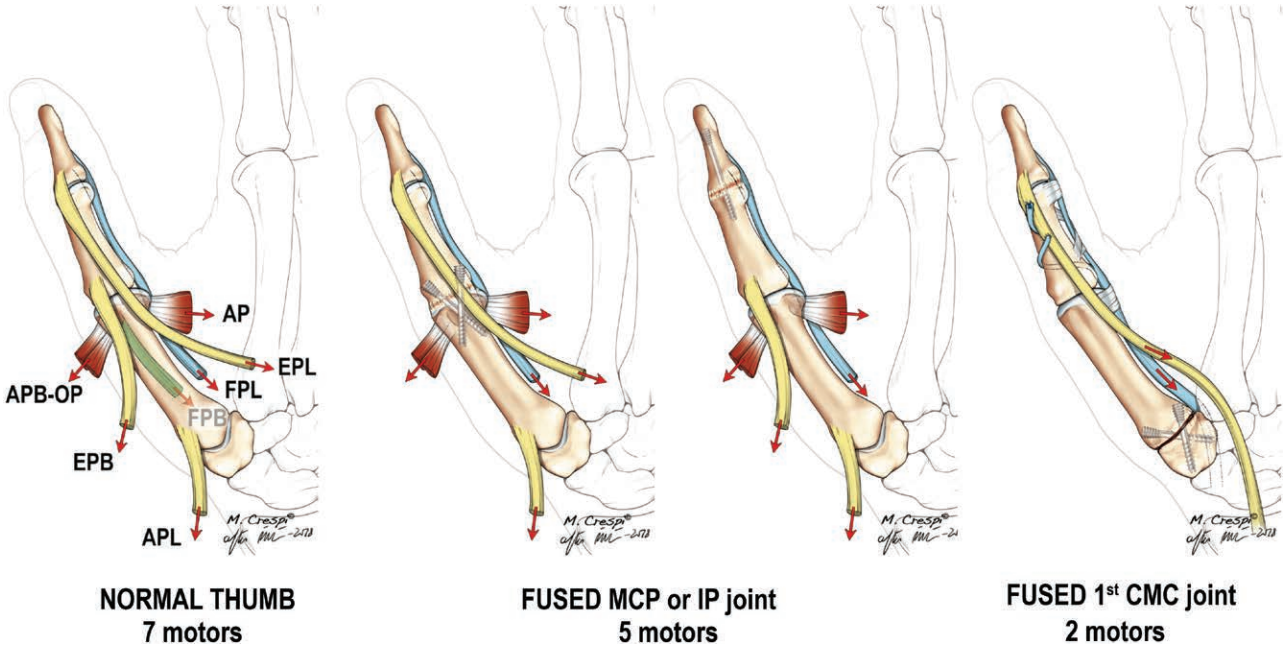

Fig. 7. A thumb with three joints requires seven functioning muscles to avoid collapse (*left*). If the interphalangeal or the metacarpophalangeal joint is fused, only five muscles will be needed (*center*). If there is no saddle joint or under an extreme dearth of tendon transfers available, basic pinch function can be achieved with just two muscles: an extensor and a flexor with a tenodesis to the interphalangeal joint (*right*). (© Dr. del Piñal 2018.)

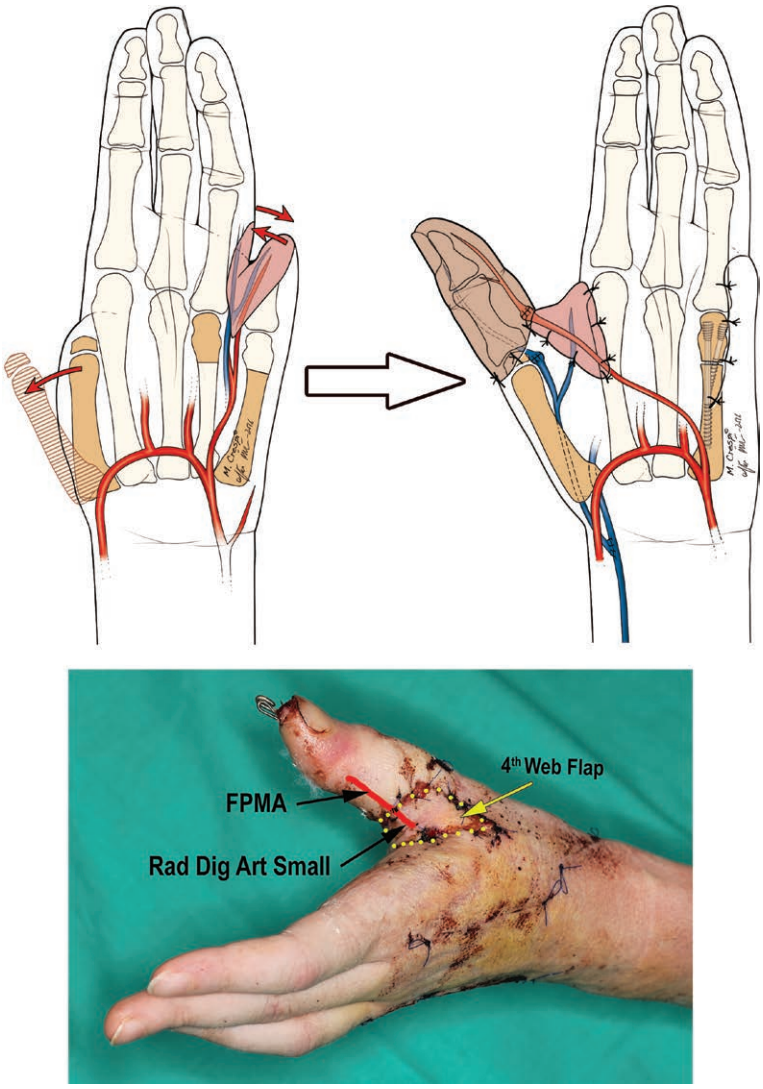

Fig. 8. (*Above*) This 22-year-old, presented in Figure 1 (patient 20), had the "happy" coincidence of having suffered an amputation of the small finger and of the thumb. At the same time as a cosmetic resection of the fifth ray, the web that would have otherwise been discarded was pedicled on the fourth common digital artery and used to replace the first web space. A trimmed hallux completed the reconstruction in the same operation. (*Below*) Notice immediate correction of the adduction contracture at 10 days. A short pedicle of plantar-type dominant hallux was anastomosed to the distal stump of the radial digital artery of the small finger. *FDMA*, first dorsal metatarsal artery. (© Dr. del Piñal 2017.)

splints is impossible if there is no thumb. Thus, it is imperative to break this vicious cycle by performing the transfer and reconstructing the web as soon as possible. Not only will patients return to their duties earlier but, most importantly, adductor muscle function will be preserved.

An elegant way of solving both problems is by transferring an index stump plus a minihallux as discussed previously. In any other instance, the surgeon has to replace the web by importing tissue. A pedicled groin flap is a very popular option, but it should be again stressed that it will effectively entail loss of function of the short muscle because of the time needed for the process to be completed. Single-stage reconstruction with free scapular and/or anterior tibial flaps is very effective for reconstructing large defects.[36,37] The cosmetic result, however, is not so pleasing:

the flap skin is not a perfect match and it tends to be chunky, mostly in the proximal aspect of the web. Careful tailoring of the flap at the time of transfer should prevent this from occurring. For the medium-size defect, we have been satisfied using fasciosubcutaneous flaps from the foot that are later skin grafted.[18] However, an unparalleled perfect fit has only been achieved when using web flaps from the foot.[17] Exceptionally, one can find a situation where the web can be harvested from the same hand (Fig. 8).

Analyzing the results in this heterogeneous group of patients is complicated because of their dissimilarities. Unfortunately, even in a busy practice, it is difficult to gather a group of identical patients of this complexity. This is obviously a limitation of this article, and even basic statistical analysis is doomed by major error. From experience, we should stress that delaying the surgery makes the procedure more difficult and the short thumb muscles more scarred or useless. Of the metacarpal hand patients, all were able to perform key pinch and six of the seven were able to perform tripod pinch. As expected, fusing any joint has a detrimental effect on the Kapandji opposition score on the more sophisticated reconstructions, but fusions were required to avoid joint collapse. Perhaps the most important (but least scientific) information can be gathered from the subjective assessment. In other words, it is important not only that the patient can pinch but also that they are happy with the cosmetic result and the acceptance of the limitations they may have. Thankfully, most of our patients rated both their reconstruction and the postoperative use of their hand very highly.

CONCLUSIONS

In summary, although contrary to current thinking, we would not recommend the standard approach for major thumb amputations of a pedicled groin flap followed by a toe. Stated advantages (i.e., sparing of recipient vessels and providing plenty of skin) are far outweighed by the functional loss of the thenar muscles, the unyielding contracture of the first metacarpal, and the difficulty of secondary surgery. Tendon transfers cannot adequately substitute for the loss of the original intrinsic muscles. In contrast, our results have led us to recommend very early reconstruction to preserve some remaining function of the intrinsic muscles. One-stage reconstructions provided consistently good results and high patient satisfaction. The proposed approach is more complex than one conducted in stages; however, multiple teams throughout the world are capable of this endeavor without undue complications, and at this point a free flap is no longer a major feat. Considerable expertise in microsurgery and understanding of the mechanics of the paralytic hand are essential to achieve a satisfactory result. Despite our positive experience, further studies are required to compare these results to those of more classic transfers.

Francisco del Piñal, M.D., Dr. Med.
Serrano 58-1B
E-28001 Madrid, Spain
drpinal@drpinal.com, pacopinal@gmail.com

REFERENCES

1. Michon J, Merle M, Bouchon Y, Foucher G. Functional comparison between pollicization and toe-to-hand transfer for thumb reconstruction. *J Reconstr Microsurg.* 1984;1:103–112.
2. Lister G. The choice of procedure following thumb amputation. *Clin Orthop Relat Res.* 1985;195:45–51.
3. Brunelli GA, Brunelli GR. Reconstruction of traumatic absence of the thumb in the adult by pollicization. *Hand Clin.* 1992;8:41–55.
4. Ishida O, Taniguchi Y, Sunagawa T, Suzuki O, Ochi M. Pollicization of the index finger for traumatic thumb amputation. *Plast Reconstr Surg.* 2006;117:909–914.
5. Graham DJ, Venkatramani H, Sabapathy SR. Current reconstruction options for traumatic thumb loss. *J Hand Surg Am.* 2016;41:1159–1169.
6. Adani R, Woo SH. Microsurgical thumb repair and reconstruction. *J Hand Surg Eur Vol.* 2017;42:771–788.
7. Lin CH, Mardini S, Lin YT, Lin CH, Chen CT, Wei FC. Osteoplastic thumb ray restoration with or without secondary toe transfer for reconstruction of opposable basic hand function. *Plast Reconstr Surg.* 2008;121:1288–1297.
8. Wei FC. Tissue preservation in hand injury: The first step to toe-to-hand transplantation. *Plast Reconstr Surg.* 1998;102:2497–2501.
9. Al-Qattan MM, Al-Qattan AM. Defining the indications of pedicled groin and abdominal flaps in hand reconstruction in the current microsurgery era. *J Hand Surg Am.* 2016;41:917–927.
10. Sabapathy SR, Venkatramani H, Bhardwaj P. Reconstruction of the thumb amputation at the carpometacarpal joint level by groin flap and second toe transfer. *Injury* 2013;44:370–375.
11. del Piñal F. Severe mutilating injuries to the hand: Guidelines for organizing the chaos. *J Plast Reconstr Aesthet Surg.* 2007;60:816–827.
12. del Piñal F, Herrero F, García-Bernal FJ, Jado E, Ros MJ. Minimizing impairment in laborers with finger losses distal to the proximal interphalangeal joint by second toe transfer. *Plast Reconstr Surg.* 2003;112:1000–1011.
13. del Piñal F. The indications for toe transfer after "minor" finger injuries. *J Hand Surg Br.* 2004;29:120–129.
14. Wei FC, Chen HC, Chuang CC, Noordhoff MS. Reconstruction of the thumb with a trimmed-toe transfer technique. *Plast Reconstr Surg.* 1988;82:506–515.
15. del Piñal F, García-Bernal FJ, Regalado J, Studer A, Ayala H, Cagigal L. A technique to improve foot appearance after trimmed toe or hallux harvesting. *J Hand Surg Am.* 2007;32:409–413.

16. Del Piñal F, Moraleda E, de Piero GH, Ruas JS, Galindo C. Onycho-osteo-cutaneous defects of the thumb reconstructed by partial hallux transfer. *J Hand Surg Am.* 2014;39:29–36.
17. Del Piñal F, Klausmeyer M, Moraleda E, de Piero GH, Rúas JS, Klich M. Foot web free flaps for single-stage reconstruction of hand webs. *J Hand Surg Am.* 2015;40:1152–1160.
18. del Piñal F, García-Bernal FJ, Delgado J, Regalado J, Sanmartín M, García-Fernández D. Overcoming soft-tissue deficiency in toe-to-hand transfer using a dorsalis pedis fasciosubcutaneous toe free flap: Surgical technique. *J Hand Surg Am.* 2005;30:111–119.
19. Kimura N, Satoh K. Consideration of a thin flap as an entity and clinical applications of the thin anterolateral thigh flap. *Plast Reconstr Surg.* 1996;97:985–992.
20. del Piñal F, García-Bernal FJ, Studer A, Ayala H, Cagigal L, Regalado J. Super-thinned iliac flap for major defects on the elbow and wrist flexion creases. *J Hand Surg Am.* 2008;33:1899–1904.
21. Lin CH, Lo S, Lin CH, Lin YT. Opponensplasty provides predictable opposable tripod pinch in toe transfer for proximal thumb ray defect reconstruction. *Plast Reconstr Surg.* 2012;130:810e–818e.
22. Barca F, Santi A, Tartoni PL, Landi A. Gait analysis of the donor foot in microsurgical reconstruction of the thumb. *Foot Ankle Int.* 1995;16:201–206.
23. Lipton HA, May JW Jr, Simon SR. Preoperative and postoperative gait analyses of patients undergoing great toe-to-thumb transfer. *J Hand Surg Am.* 1987;12:66–69.
24. Foucher G, Merle M, Maneaud M, Michon J. Microsurgical free partial toe transfer in hand reconstruction: A report of 12 cases. *Plast Reconstr Surg.* 1980;65:616–627.
25. Foucher G. Twisted two toes technique in thumb reconstruction. In: Landi A, ed. *Reconstruction of the Thumb.* London: Chapman; 1989:275–279.
26. del Piñal F. Vascularized joint and hemi-joint flap. In: Moran S, Chung K, eds. *ASSH Surgical Anatomy: Flap Reconstruction.* Chicago, Ill: American Society for Surgery of the Hand; 2018:321–336.
27. Barbato BD, Leblanc P, Lemerle JP. Thumb reconstruction by pollicization of an index finger stump combined with a wrap-around flap from the big toe. *J Hand Surg Br.* 1998;23:69–71.
28. Raja Sabapathy S, Sebastin SJ, Venkatramani H, Balaji G. Primary use of the index finger for reconstruction of amputated thumbs. *Br J Plast Surg.* 2004;57:50–60.
29. Gordon L, Rosen J, Alpert BS, Buncke HJ. Free microvascular transfer of second toe ray and serratus anterior muscle for management of thumb loss at the carpometacarpal joint level. *J Hand Surg Am.* 1984;9:642–644.
30. Mitz V. Second toe to thumb transfer with extensor digitorum brevis opponensplasty. *Ann Plast Surg.* 1986;17:259–262.
31. Vilkki SK, Kotkansalo T. Present technique and long-term results of toe-to-antebrachial stump transplantation. *J Plast Reconstr Aesthet Surg.* 2007;60:835–848.
32. Henz VR, Lecrercq C. *Surgical Rehabilitation of the Upper Limb in Tetraplegia.* New York: Saunders; 2002.
33. Van Heest AE. Tetraplegia. In: Wolfe SW, Hotchkiss RN, Peterson WC, Kozin SH, eds. *Green's Operative Hand Surgery.* Philadelphia: Elsevier Churchill Livingstone; 2013:1122–1145.
34. Zancolli E. *Structural & Dynamic Bases of Hand Surgery.* 2nd ed. Philadelphia: Lippincott; 1979.
35. Del Piñal F, García-Bernal FJ, Delgado J. Is posttraumatic first web contracture avoidable? Prophylactic guidelines and treatment-oriented classification. *Plast Reconstr Surg.* 2004;113:1855–1860.
36. Fan CY, Jiang J, Zeng BF, Jiang PZ, Cai PH, Chung KC. Reconstruction of thumb loss complicated by skin defects in the thumb-index web space by combined transplantation of free tissues. *J Hand Surg Am.* 2006;31:236–241.
37. Zhang YX, Wang D, Zhang Y, et al. Triple chimeric flap based on anterior tibial vessels for reconstruction of severe traumatic injuries of the hand with thumb loss. *Plast Reconstr Surg.* 2009;123:268–275.